World Journal of Advanced Research and Reviews
eISSN: 2581-9615 CODEN (USA): WJARAI
Cross Ref DOI: 10.30574/wjarr
Journal homepage: https://wjarr.com/

(CASE REPORT)

DELAYED DIAGNOSIS OF VOLAR LUNATE DISLOCATION ASSOCIATED WITH SCAPHOID AND DISTAL RADIUS FRACTURES: A CASE REPORT

Mohammed LAHMAIDI *, Youssef JALAL, Hicham BOUSBAA, Mourad BENNANI, Hassane ZEJJARI and Taoufik CHERRAD

Department of Orthopaedic and Trauma Surgery, Moulay Ismail Military Hospital, Meknes, Morocco.
* Corresponding Author

ORCID Details
Mohammed LAHMAIDI: https://orcid.org/0009-0007-2828-9239
Youssef JALAL: https://orcid.org/0000-0002-5255-8095
Hicham BOUSBAA: https://orcid.org/0000-0002-9687-8066
Mourad BENNANI: https://orcid.org/0000-0002-5535-3933
Hassane ZEJJARI: https://orcid.org/0009-0003-8270-3235
Taoufik CHERRAD: https://orcid.org/0000-0002-4656-9265

World Journal of Advanced Research and Reviews, 2026, 32(02), 1145–1148

Publication history: Received on 10 October 2026; revised on 16 November 2026; accepted on 18 November 2026

Article DOI: https://doi.org/10.30574/wjarr.2026.32.2.2948

Copyright © 2026 Author(s) retain the copyright of this article. This article is published under the terms of the Creative Commons Attribution License 4.0

ABSTRACT

Volar lunate dislocation is an uncommon wrist injury that may be overlooked when associated fractures dominate the initial assessment. We report the case of an 18-year-old right-handed woman with a left volar lunate dislocation associated with scaphoid and distal radius fractures, diagnosed seven days after trauma. Initial treatment consisted of plaster immobilization for the distal radius fracture. Persistent pain, functional impairment, and median nerve distribution dysesthesia prompted reassessment. Surgical exploration revealed complete lunotriquetral ligament rupture, partial scapholunate ligament injury, and hourglass-shaped constriction of the median nerve without discontinuity. Treatment comprised open reduction, scaphoid screw fixation, suture-anchor ligament repair, temporary intercarpal Kirschner-wire stabilization, carpal tunnel decompression, and extrafascicular neurolysis. The wires were removed approximately one month after surgery, followed by rehabilitation. At approximately ten weeks, wrist mobility approached that of the contralateral side, and median nerve symptoms had resolved. This case highlights the importance of systematically assessing carpal alignment and neurological status in wrist trauma, including when an associated fracture has already been identified.

Keywords: Lunate dislocation; Scaphoid fracture; Distal radius fracture; Median nerve compression; Delayed diagnosis

1 INTRODUCTION

Perilunate dislocations and fracture-dislocations are complex wrist injuries involving variable combinations of osseous and ligamentous disruption. Despite their severity, they may be missed at initial assessment. An initially overlooked

diagnosis was documented in 25% of injuries in a multicenter series [1]. Careful evaluation of radiocarpal and intercarpal alignment is therefore essential when interpreting wrist radiographs [2].

Volar lunate dislocation associated with scaphoid fracture has previously been described and may require combined fracture fixation and intercarpal stabilization [3]. The accompanying neurological involvement adds to the complexity of management. We present an initially missed volar lunate dislocation associated with scaphoid and distal radius fractures, intrinsic ligament injuries, and symptomatic median nerve compression.

2 CASE PRESENTATION

An 18-year-old right-handed woman presented with persistent pain and functional impairment of the left wrist seven days after closed trauma. The initial assessment had identified a distal radius fracture, which was treated with plaster immobilization. Persistent symptoms, including dysesthesia in the median nerve distribution, prompted further clinical and radiographic evaluation.

Radiographs demonstrated volar lunate dislocation associated with a displaced scaphoid fracture and the previously identified distal radius fracture (Figure 1). Operative treatment was undertaken to restore carpal alignment, stabilize the associated injuries, and address the neurological symptoms.

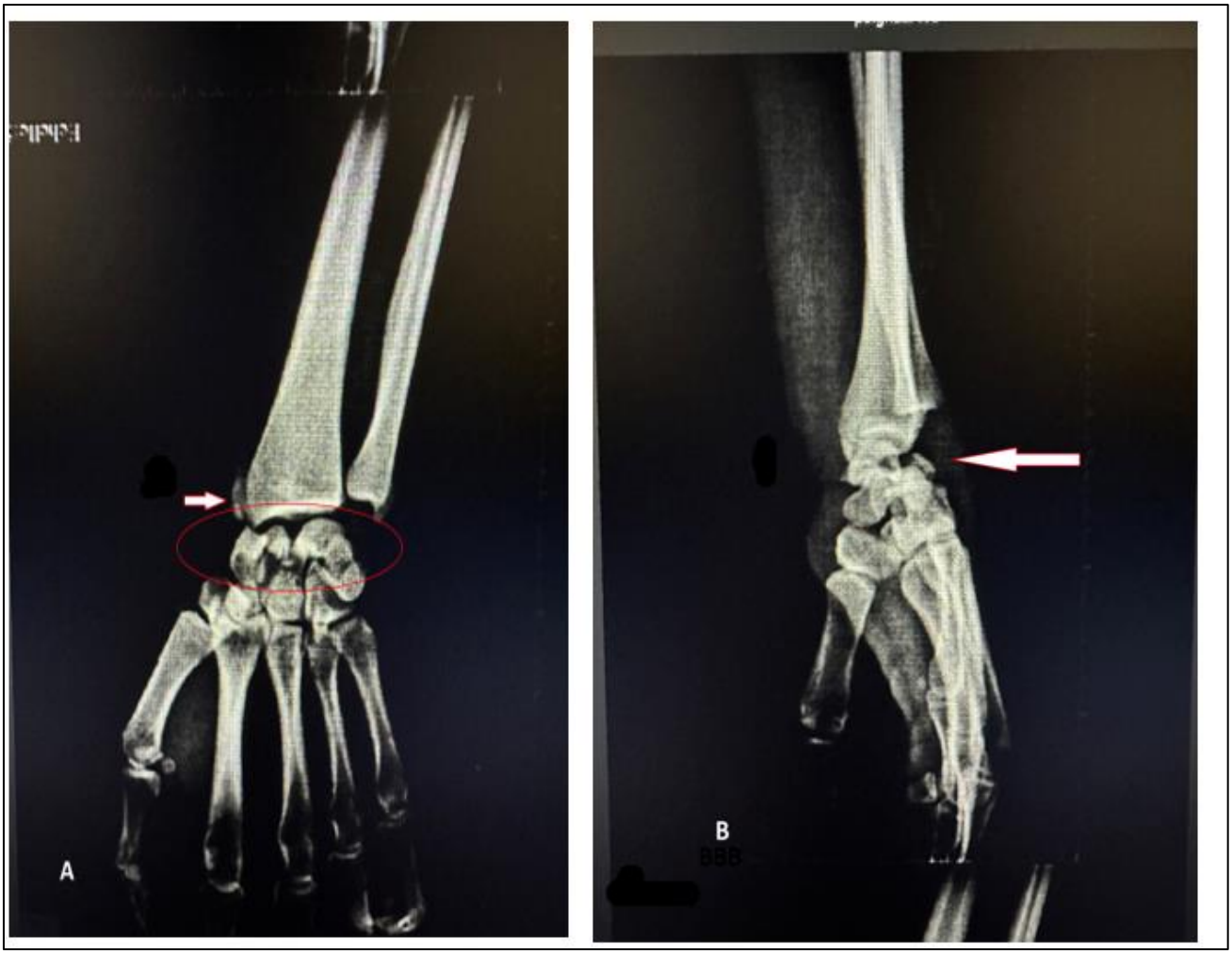

Figure 1: Preoperative anteroposterior (A) and lateral (B) radiographs of the left wrist demonstrating the carpal injury and associated fractures.

Open exploration revealed complete rupture of the lunotriquetral ligament and a partial scapholunate ligament injury. The lunate was reduced, and the scaphoid fracture was stabilized with a headless compression screw. Ligament repair was performed using suture anchors and supplemented with temporary intercarpal Kirschner-wire fixation.

Median nerve exploration demonstrated an hourglass-shaped segmental constriction without loss of continuity. Carpal tunnel decompression and extrafascicular neurolysis were performed.

Postoperative radiographs documented the reduction and fixation construct (Figure 2). The Kirschner wires were removed approximately one month after surgery, followed by functional rehabilitation.

At approximately ten weeks postoperatively, wrist mobility approached that of the contralateral side, and median nerve symptoms had resolved. Quantitative range-of-motion measurements, grip-strength testing, and validated functional scores were not available.



Figure 2: Postoperative anteroposterior (A) and lateral (B) radiographs following scaphoid screw fixation and temporary intercarpal Kirschner-wire stabilization.

3 DISCUSSION

Volar lunate dislocation is a severe carpal injury that requires recognition of both the displacement and the associated osseoligamentous lesions. An accompanying fracture may divert attention from carpal alignment and contribute to an incomplete initial diagnosis [1,2]. In this case, the distal radius fracture was identified initially, whereas the carpal injury was recognized seven days later.

Persistent pain and neurological symptoms were important features prompting reassessment. A systematic review of the radiographs should include the relationships between the distal radius, lunate, and capitate, together with assessment of associated carpal fractures [2]. The presence of a distal radius fracture should not preclude further investigation of abnormal carpal alignment.

The combination of scaphoid fracture and intrinsic ligament disruption requires treatment directed at both components of the injury. Reduction and scaphoid fixation restore the osseous relationships, while ligament repair and temporary stabilization address intercarpal instability [2,3]. In the present case, complete lunotriquetral rupture and partial scapholunate injury were treated with suture-anchor repair and temporary intercarpal pinning.

Treatment delay is associated with less favorable outcomes, particularly in chronic injuries [4]. However, the available evidence is predominantly observational, and the effect of a short delay cannot be determined for an individual patient. Recognition of the injury and restoration of alignment remain central objectives even after an initially missed diagnosis.

The operative approach should allow adequate assessment and treatment of the identified lesions. Current evidence does not demonstrate a clear difference between surgical approaches in measured functional outcomes [5]. Consequently, this case supports the feasibility of the treatment performed but cannot establish its superiority over alternative techniques.

Median nerve dysfunction is a recognized complication of perilunate injuries and volar lunate displacement [2,4]. Persistent dysesthesia in this patient was associated with an intraoperative hourglass-shaped constriction without nerve discontinuity. Decompression and extrafascicular neurolysis were performed to address the compression. The nerve appearance represents a notable operative finding, although its specific mechanism and independent prognostic significance cannot be established from a single observation.

The short-term clinical evolution was favorable, with wrist mobility approaching that of the contralateral side and resolution of median nerve symptoms. Nevertheless, the absence of quantitative functional measurements limits objective assessment of recovery. Longer clinical and radiographic follow-up is required to evaluate scaphoid union, maintenance of carpal alignment, residual instability, and degenerative changes.

4 CONCLUSION

Volar lunate dislocation may be overlooked when associated fractures dominate the initial assessment. Persistent pain, functional impairment, and median nerve symptoms should prompt reassessment of carpal alignment. Treatment must address the associated fractures, ligament injuries, and neurological compression. Favorable short-term recovery was achieved in this patient, although longer follow-up is necessary to assess the durability of the result.

STATEMENTS ON COMPLIANCE WITH ETHICAL STANDARDS

Disclosure of conflict of interest

The authors declare no conflicts of interest.

Statement of informed consent

Written informed consent was obtained from the patient for publication of this case report and the accompanying anonymized images.

REFERENCES

[1] Herzberg G, Comtet JJ, Linscheid RL, Amadio PC, Cooney WP, Stalder J. Perilunate dislocations and fracture-dislocations: a multicenter study. J Hand Surg Am. 1993;18(5):768–779. doi:10.1016/0363-5023(93)90041-Z.

[2] Stanbury SJ, Elfar JC. Perilunate dislocation and perilunate fracture-dislocation. J Am Acad Orthop Surg. 2011;19(9):554–562. doi:10.5435/00124635-201109000-00006.

[3] Alshehri D, Mousa A, Al Ahmadi B. Trans-scaphoid lunate dislocation rare injury: a case report. Cureus. 2023;15(8):e44072. doi:10.7759/cureus.44072.

[4] van der Oest MJW, Duraku LS, Artan M, Hundepool CA, Power DM, Rajaratnam V, et al. Perilunate injury timing and treatment options: a systematic review. J Wrist Surg. 2022;11(2):164–176. doi:10.1055/s-0041-1735841.

[5] Abola MV, Gerber BA, Rocks MC, Chen JS, Hacquebord JH, Azad A. A comparison of outcomes in acute perilunate injuries: systematic review and meta-analysis of treatment approaches. Hand (N Y). 2025;20(5):725–732. doi:10.1177/15589447241231291.