World Journal of Advanced Research and Reviews
eISSN: 2581-9615 CODEN (USA): WJARAI
Cross Ref DOI: 10.30574/wjarr
Journal homepage: https://wjarr.com/

(CASE REPORT)

SINONASAL RHABDOMYOSARCOMA IN A 7-YEAR-OLD: A CASE REPORT AND LITERATURE REVIEW

Bilal EL ALAOUI *, Khadija AMSSAYEF, Abdelkarim UAKKAS, Samia KHALFI, Kaoutar SOUSSY, Wissal HASSANI, Fatima Zahraa FARHANE, Zenab ALAMI and Touria BOUHAFA

Department of Radiation Oncology, Hassan II University Hospital, Fez, Morocco.
* Corresponding Author

World Journal of Advanced Research and Reviews, 2026, 32(02), 1040–1045

Publication history: Received on 09 October 2026; revised on 14 November 2026; accepted on 17 November 2026

Article DOI: https://doi.org/10.30574/wjarr.2026.32.2.2929

Copyright © 2026 Author(s) retain the copyright of this article. This article is published under the terms of the Creative Commons Attribution License 4.0

ABSTRACT

Rhabdomyosarcoma (RMS) is the most common soft tissue sarcoma in children. Although the head and neck region is frequently affected, sinonasal involvement is rare and may present diagnostic challenges due to its nonspecific clinical features and locally invasive behavior. Diagnosis relies on imaging, histopathological examination, and immunohistochemical studies. Treatment requires a multidisciplinary approach, usually combining chemotherapy with surgery and/or radiotherapy.

We report the case of A 7-year-old boy presented with a one-month history of unilateral nasal obstruction. Computed tomography (CT) revealed an extensive polypoid lesion involving the right nasal cavity, paranasal sinuses, choanae, nasopharynx, and oropharynx. Histopathological and immunohistochemical examinations confirmed botryoid embryonal rhabdomyosarcoma. The patient received five cycles of ifosfamide, vincristine, and actinomycin D (IVA) chemotherapy, followed by radiotherapy (50.4 Gy in 28 fractions) and four additional cycles of IVA. Surgery was not performed due to logistical constraints during the COVID-19 pandemic. Follow-up imaging showed a complete radiological response, with no evidence of residual or recurrent disease.

Keywords: Rhabdomyosarcoma, Sinonasal Tumor, Pediatric Oncology, Radiotherapy.

1 INTRODUCTION

Rhabdomyosarcoma (RMS) is a malignant soft tissue tumor of mesenchymal origin, arising from primitive cells that fail to fully differentiate into mature skeletal muscle cells. It represents approximately 5% of malignant neoplasms in children, being the most common sarcoma in pediatric population. [1] The most common site of occurrence are the head and neck regions, while sinonasal involvement remains rare and may present diagnostic challenges due to its nonspecific symptoms and locally invasive behavior. [2,3]

The clinical presentation is often nonspecific, with symptoms such as nasal obstruction, epistaxis, facial swelling, or persistent sinonasal complaints, which may initially resemble more common inflammatory or infectious conditions. Consequently, diagnosis may be delayed. Imaging, particularly magnetic resonance imaging (MRI), plays an essential role in defining the extent of the primary tumor and evaluating its relationship with adjacent critical structures.

Definitive diagnosis relies on histopathological examination supported by immunohistochemical and molecular studies. [3-6]

The management of pediatric RMS requires a multidisciplinary approach; treatment generally combines systemic chemotherapy with local control through surgery and/or radiotherapy, according to the tumor site, histological and molecular characteristics, disease extent, and risk group. [1,2]

2 CASE PRESENTATION

We report the case of a 7-year-old boy with no significant medical history who presented with one month of unilateral nasal obstruction and a polypoid mass occupying the right nasal cavity. Computed tomography (CT) revealed opacification of the right paranasal sinuses and right nasal cavity, extending posteriorly into both choanae and the nasopharynx, and inferiorly into the oropharynx, where it appeared as a 25-mm polypoid lesion (Fig. 1).

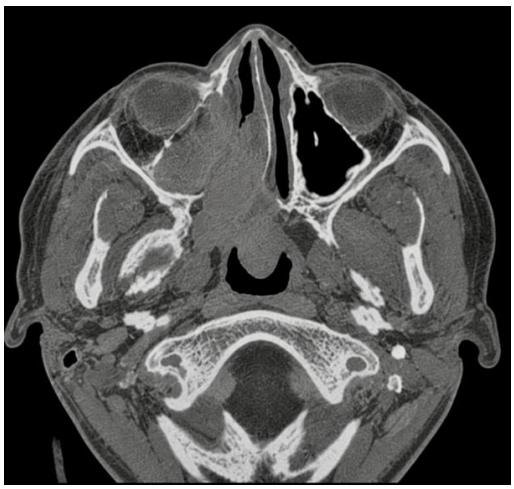

Figure 1: Axial CT scan showing opacification of the right paranasal sinuses and right nasal cavity, extending posteriorly into both choanae and the nasopharynx, and inferiorly into the oropharynx.

Histopathological and immunohistochemical evaluation confirmed the diagnosis of embryonal rhabdomyosarcoma of botryoid type.

The patient initially received five cycles of combination chemotherapy with ifosfamide, vincristine, and actinomycin D (IVA). However, surgery could not be performed due to logistical constraints related to the COVID-19 pandemic. He subsequently underwent radiotherapy (50.4 Gy delivered in 28 fractions) targeting the sinonasal region, followed by four additional cycles of IVA chemotherapy (Fig. 2).

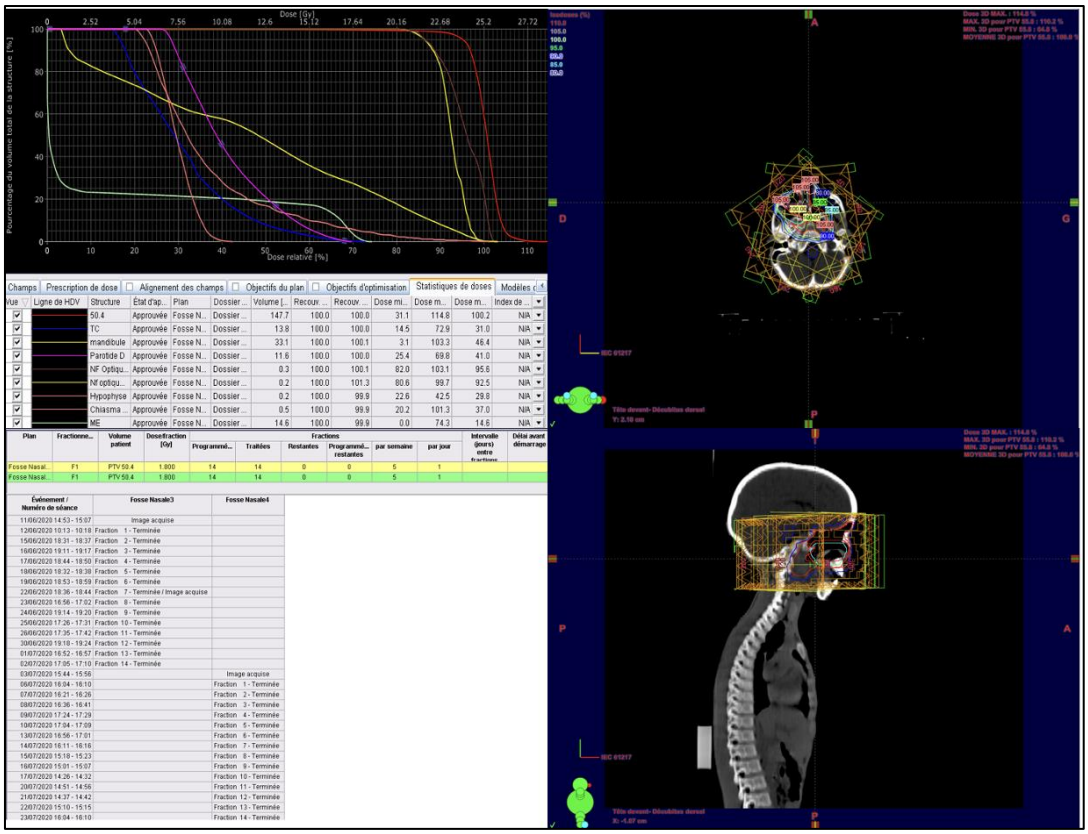

Figure 2: Radiotherapy treatment planning and dose evaluation.

Follow-up imaging demonstrated significant tumor regression, with no evidence of residual disease, abnormal signal intensity, or pathological contrast enhancement in the sinonasal region, and no signs of recurrence (Fig. 3).



Figure 3: Axial T2-weighted MRI showing complete radiological response, with no evidence of residual or recurrent sinonasal disease.

3 DISCUSSION

Sinonasal rhabdomyosarcoma (RMS) is rare in children, although RMS is the most common soft tissue sarcoma in this age group. It accounts for approximately 2.7% of childhood cancers, with around half of cases occurring during the first decade of life. The head and neck region represents about 25% of cases, including parameningeal sites such as the nasal cavity, paranasal sinuses, and nasopharynx. [7,8,10]

In a study of 157 pediatric patients with sinonasal RMS, the mean age at diagnosis was 9.38 years. The nasal cavity was the most common site 31.8%, followed by the maxillary sinus 30.6%. Embryonal RMS accounted for 32.5% of cases. [9]

Our patient was diagnosed at 7 years of age, within the age range commonly reported in pediatric RMS.

The clinical presentation of sinonasal RMS is often nonspecific and depends on tumor location, size, local extension, and presence of metastatic disease. Initial symptoms may resemble common inflammatory or upper respiratory conditions, potentially delaying diagnosis. Nasal obstruction is one of the most frequent symptoms and may be accompanied by rhinorrhea, persistent sinusitis, or epistaxis. With local progression, the tumor may extend into adjacent structures, causing facial swelling, pain, proptosis, or diplopia. In parameningeal RMS, persistent headache or cranial nerve deficits may suggest skull base or intracranial involvement. [8,11,12]

In our patient, the disease presented as a one-month history of unilateral nasal obstruction, with a polypoid mass occupying the right nasal cavity.

Imaging plays an essential role in the diagnosis, staging, treatment planning, and follow-up of sinonasal RMS. CT is useful for assessing bone involvement and skull base erosion, whereas MRI is preferred for evaluating tumor extent and invasion of adjacent soft tissues, the orbit, and intracranial structures. MRI is also important for assessing treatment response, although post-treatment inflammation and fibrosis may complicate the interpretation of residual abnormalities. [8,12]

FDG PET/CT or PET/MRI can help detect nodal and distant metastases. However, chest CT remains more sensitive for pulmonary metastases and should not be replaced by PET imaging. [8,14]

Regional lymph node involvement is an important prognostic factor in RMS, occurring in approximately 23% of pediatric cases. In a series of 40 patients with sinonasal RMS, nodal metastases were reported in 17.5% of cases and were associated with poorer survival. Cervical and retropharyngeal lymph nodes should therefore be carefully assessed during initial staging. [7,8,13]

Approximately 15–20% of children with RMS have distant metastases at diagnosis, most commonly involving the lungs, bone marrow, bones, and distant lymph nodes. In the study of 157 pediatric patients with sinonasal RMS, the 5-year overall survival rate was 24.4% in patients with metastases, compared with 61.5% in those without metastatic disease. Complete staging is therefore essential, even in the absence of symptoms. [8,9]

In our patient, CT showed extensive involvement of the nasal cavity and paranasal sinuses, extending posteriorly into both choanae and the nasopharynx and inferiorly into the oropharynx. No regional lymph node involvement or distant metastatic disease was documented.

Histopathological examination is essential for diagnosing RMS and distinguishing it from other sinonasal malignancies. Embryonal RMS is characterized by primitive round or spindle-shaped cells embedded in a loose myxoid stroma. The botryoid pattern typically shows a polypoid, grape-like appearance with a subepithelial cambium layer. [15,16]

Immunohistochemistry, particularly desmin, myogenin, and MyoD1, helps confirm skeletal muscle differentiation. Molecular testing for FOXO1 gene fusions is useful for classification and prognostic assessment, especially in suspected alveolar RMS. [7,16,17]

In our patient, histopathological and immunohistochemical findings confirmed embryonal RMS with botryoid morphology.

The prognosis of pediatric RMS depends on several factors, including age, tumor location and size, histological subtype, lymph node involvement, metastatic status, and response to treatment. [7] Children aged 1–9 years generally have better outcomes, with a reported 5-year overall survival of approximately 87%. Our patient's age of 7 years is therefore

a favorable factor. However, sinonasal RMS is classified as a parameningeal tumor, an unfavorable site because of its proximity to the skull base and intracranial structures. [7,12]

Other factors associated with poorer survival include skull base infiltration, lymph node involvement, advanced IRS group, and tumor size of at least 5 cm, as reported in a retrospective series of 40 patients with sinonasal RMS. [13] Embryonal RMS generally has a more favorable prognosis than fusion-positive alveolar RMS, making molecular testing, particularly FOXO1 fusion status, important for risk assessment. [7]

The treatment of pediatric sinonasal RMS requires a multidisciplinary approach combining chemotherapy with local treatment, including surgery and radiotherapy. The choice of treatment depends on tumor extent, resectability, histological subtype, and risk group. The main objectives are to achieve local and systemic disease control while preserving vital structures and limiting long-term complications. [7,12,18]

Chemotherapy is an essential component of treatment. European protocols commonly use the IVA regimen (ifosfamide, vincristine, and actinomycin D), whereas North American protocols generally use VAC (vincristine, actinomycin D, and cyclophosphamide). Treatment duration and intensity depend on the patient's risk group and disease characteristics. [7,18]. Surgery is considered when complete tumor removal is possible without major functional or cosmetic consequences. However, extensive sinonasal tumors may involve the orbit, skull base, or adjacent critical structures, making complete resection difficult or potentially mutilating. In these cases, treatment generally relies on chemotherapy and radiotherapy, with surgery reserved for selected patients. [7,12,19]

Radiotherapy plays an important role in parameningeal RMS, particularly in unresectable tumors or in the presence of macroscopic residual disease after induction chemotherapy. Intensity-modulated radiation therapy (IMRT) and volumetric modulated arc therapy (VMAT) allow precise dose delivery while reducing exposure of surrounding organs at risk, including the optic pathways and brain. [7,12,18] The prescribed dose depends on tumor resectability, response to chemotherapy, and the treatment protocol. The 2024 German recommendations include 50.4 Gy in 28 fractions for unresectable tumors with an incomplete response to induction chemotherapy, while lower doses may be indicated in other clinical situations. [18]

In our patient, treatment consisted of five cycles of IVA chemotherapy, followed by radiotherapy to the sinonasal region (50.4 Gy in 28 fractions), and four additional cycles of IVA. Surgery was not performed because of logistical constraints related to the COVID-19 pandemic. Follow-up MRI showed a complete radiological response, suggesting good disease control following combined treatment. However, this outcome cannot be attributed to radiotherapy alone or used to establish the superiority of omitting surgery.

Long-term follow-up is essential to detect recurrence and monitor late treatment-related effects. It should include clinical examination, nasal endoscopy when appropriate, and MRI of the primary site, with additional investigations guided by the initial disease stage and clinical findings. [7,8]

4 CONCLUSION

Sinonasal embryonal RMS is a rare pediatric tumor that may present with nonspecific symptoms. Early diagnosis and accurate staging are essential. Treatment requires a multidisciplinary approach combining chemotherapy and local treatment. This case highlights the role of radiotherapy, with a complete radiological response following combined treatment. Long-term follow-up is necessary to monitor for recurrence and late effects.

STATEMENTS ON COMPLIANCE WITH ETHICAL STANDARDS

Disclosure of conflict of interest

All authors have no conflict of interest to declare.

Statement of ethical approval

This case report was conducted in accordance with ethical guidelines.

Statement of informed consent

The patient provided informed consent for the publication of this case report.

REFERENCES

[1] Leiner J, Le Loarer F. The current landscape of rhabdomyosarcomas: an update. Virchows Arch. 2020;476:97-108. doi:10.1007/s00428-019-02676-9

[2] Mariana P Rodríguez-Vargas, Francisco G Villanueva-Sánchez. Rhabdomyosarcoma of the head and neck in pediatric patients: a systematic review. Med Oral Patol Oral Cir Bucal. 2022 Sep 29;27(6):e569–e577. doi: 10.4317/medoral.25508

[3] Larson JH, Rutledge R, Hunnell L, Choi DK, Kellogg RG, Naran S. Nasal embryonal rhabdomyosarcoma in the pediatric population: literature review and report of midline presentation. Plast Reconstr Surg Glob Open. 2021;9(4):e3534. doi: 10.1097/GOX.0000000000003534.

[4] Herrmann BW, Sotelo-Avila C, Eisenbeis JF. Pediatric sinonasal rhabdomyosarcoma: three cases and a review of the literature. Am J Otolaryngol. 2003;24(3):174–180. doi: 10.1016/S0196-0709(03)00025-5.

[5] J. Zhu, J. Zhang, G. Tang, et al. Computed tomography and magnetic resonance imaging observations of rhabdomyosarcoma in the head and neck Oncol Lett, 8 (2014), pp. 155-160. doi: 10.3892/ol.2014.2094

[6] Carina A Dehner, Erin R Rudzinski, Jessica L Davis. Rhabdomyosarcoma: Updates on classification and the necessity of molecular testing beyond immunohistochemistry Hum Pathol. 2024 May:147:72-81.doi: 10.1016/j.humpath.2023.12.004.

[7] National Cancer Institute. Childhood Rhabdomyosarcoma Treatment (PDQ®)–Health Professional Version. Bethesda, MD: National Cancer Institute. Official NCI reference.

[8] van Ewijk R, et al. European guideline for imaging in paediatric and adolescent rhabdomyosarcoma: joint statement by the European Paediatric Soft Tissue Sarcoma Study Group, the Cooperative Weichteilsarkom Studiengruppe and the Oncology Task Force of the European Society of Paediatric Radiology. Pediatr Radiol. 2021.
doi: 10.1007/s00247-021-05081-0.

[9] Sana H Siddiqui et al. Clinicopathologic traits and prognostic factors associated with pediatric sinonasal rhabdomyosarcoma. Int Forum Allergy Rhinol. 2019;9(4):363–369. doi: 10.1002/alr.22267.

[10] DJ Gerth et al. Pediatric sinonasal tumors in the United States: incidence and outcomes. Int J Pediatr Otorhinolaryngol. 2014.
doi: 10.1016/j.jss.2014.04.004

[11] Norhafiza Mat Lazim et al. Multidisciplinary approach to children with sinonasal tumors: A review. Pediatr Investig. 2019 Sep 26;3(3):173–179.doi: 10.1002/ped4.12147

[12] Nicole J M Freling et al. Imaging findings in craniofacial childhood rhabdomyosarcoma. Pediatr Radiol. 2010. Nov; 40(11):1723-38; quiz 1855.doi: 10.1007/s00247-010-1787-3.

[13] Wanpeng Li et al. Therapeutic outcome and prognostic factors in sinonasal rhabdomyosarcoma: a single-institution case series. J Cancer Res Clin Oncol 2019 Nov;145(11):2793-2802.doi: 10.1007/s00432-019-03009-8. Epub 2019 Aug 23.

[14] Federico Mercolini et al. Role of 18F-FDG-PET/CT in the staging of metastatic rhabdomyosarcoma: a report from the European Paediatric Soft Tissue Sarcoma Study Group. Eur J Cancer. 2021 Sep:155:155-162. doi: 10.1016/j.ejca.2021.07.006.Epub 2021 Aug 9.

[15] David M Parham et al. Classification of Rhabdomyosarcoma and Its Molecular Basis. Adv Anat Pathol. 2013 Nov;20(6):387–397. doi: 10.1097/PAP.0b013e3182a92d0d

[16] Lester Dr Thompson et al. Small round blue cell tumors of the sinonasal tract: a differential diagnosis approach. Mod Pathol. 2017. Jan;30(s1):S1-S26. doi: 10.1038/modpathol.2016.119.

[17] Kumar S et al. Myogenin is a specific marker for rhabdomyosarcoma: An immunohistochemical study in paraffin-embedded tissues. Mod Pathol. 2000;13:988–993. doi: 10.1038/modpathol.3880179.

[18] German Society for Pediatric Oncology and Hematology. Rhabdomyosarcoma: Standard Clinical Practice Document. 2024.

[19] Fyrmpas G al. Management of paediatric sinonasal rhabdomyosarcoma. J Laryngol Otol. 2009;123(9):990–996. doi: 10.1017/S0022215109005337.