

Primary cutaneous high-grade centrofollicular B-cell lymphoma: A case of complete response achieved with precise 3D conformal radiotherapy

Fatima Zohra Zaanoun *, Hanane Zemmari, Samia Khalfi, Kaoutar Soussy, Wissal Hassani, Fatima Zahra Farhane, Zenab Alami and Touria Bouhafa

Radiation Oncology Department, Oncology Hospital, Hassan II University Hospital, Fez 30050, Morocco.

World Journal of Advanced Research and Reviews, 2026, 30(03), 1334-1339

Publication history: Received on 25 April 2026; revised on 15 June 2026; accepted on 17 June 2026

Article DOI: <https://doi.org/10.30574/wjarr.2026.30.3.1702>

Abstract

Primary cutaneous high-grade centrofollicular B-cell lymphoma, in its localized form, represents a rare entity requiring a therapeutic strategy that optimizes local control while minimizing toxicity. This is illustrated by the case of a 43-year-old male with a tumor lesion on the upper back, progressively evolving over 7 months. Biopsy confirmed a high-grade centrofollicular B-cell lymphoma (Ki-67 >70%), staged as T2aN0M0 following extension work-up. The chosen treatment was definitive, curative-intent three-dimensional conformal radiotherapy (3D-CRT), delivering a total dose of 40 Gy in 20 fractions, planned meticulously to achieve an optimized dose distribution. Treatment tolerance was excellent, limited to a grade 1 radiation dermatitis. The 3-month evaluation revealed a complete clinical and radiological remission with sustained locoregional control. This case demonstrates that this conventional yet precisely applied technique, through rigorous target volume delineation and an adapted prescription, provides a robust and accessible therapeutic option, achieving optimal tumor control with minimal toxicity in these localized aggressive cutaneous B-cell lymphomas. Categories: Radiation Oncology, Oncology, Dermatology

Keywords: 3D Conformal Radiotherapy (3D-CRT); High-Grade / Centrofollicular; locoregional Control; Minimal Toxicity; Primary Cutaneous B-Cell Lymphoma

1. Introduction

Primary cutaneous B-cell lymphoma (PCBCL) of the centrofollicular type is a rare entity among non-Hodgkin lymphomas, characterized by an exclusive cutaneous tropism without initial extracutaneous involvement. The localized, high-grade form (Ki-67 >30-40%) is particularly rare yet clinically aggressive, with a recognized risk of progression [1, 2]. Its therapeutic management, not standardized by large prospective trials, must balance radical efficacy to prevent local relapse with minimal toxicity to preserve quality of life [3]. Historically, electron beam radiotherapy has been the cornerstone of treatment for localized disease, offering excellent local control [4]. Today, three-dimensional conformal radiotherapy (3D-CRT) and more advanced techniques such as IMRT enable more precise dose distribution, tailored to the lesion's shape and depth, while sparing adjacent healthy tissues [5, 6]. We report a case of a localized, high-grade centrofollicular PCBCL successfully treated with definitive, curative-intent 3D-CRT alone and discuss the role of this optimized treatment modality in the current therapeutic arsenal, in light of recent literature.

2. Case presentation

A 43-year-old man, with no significant medical history, presented with multiple firm, erythematous skin lesions on the upper back. The lesions had been slowly progressing and were moderately pruritic for seven months. Physical examination revealed a dominant 5-cm mammillated, erythematous tumor with a central crust and two smaller satellite

* Corresponding author: Fatima Zohra Zaanoun

plaques (3 cm in greatest diameter) on the posterior thorax (Figure 1). No palpable lymphadenopathy was detected in the cervical, axillary, or inguinal regions.

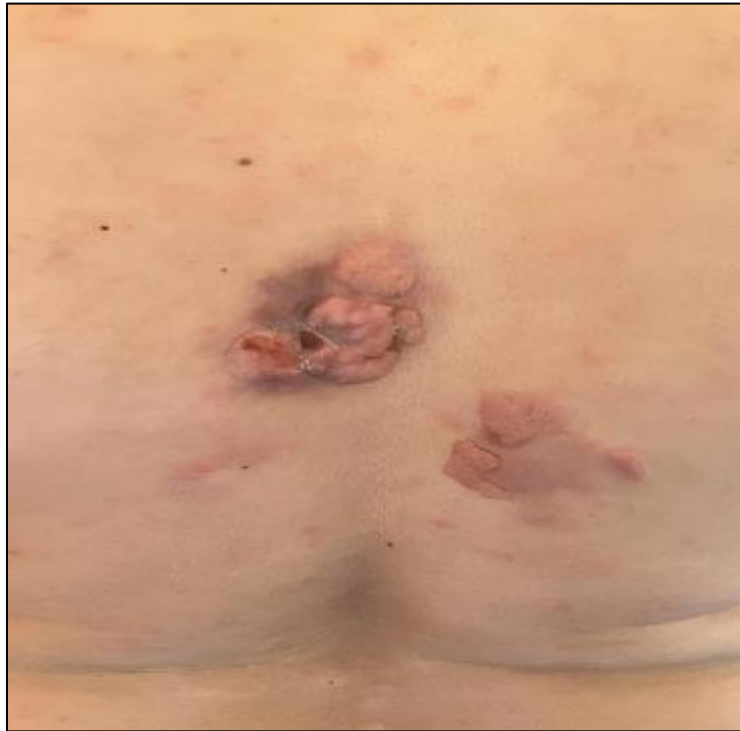

Figure 1 Initial Clinical Presentation. Photograph of the patient's upper back showing the dominant, mammillated, erythematous tumor (5 cm) with central crusting and an adjacent smaller satellite plaque

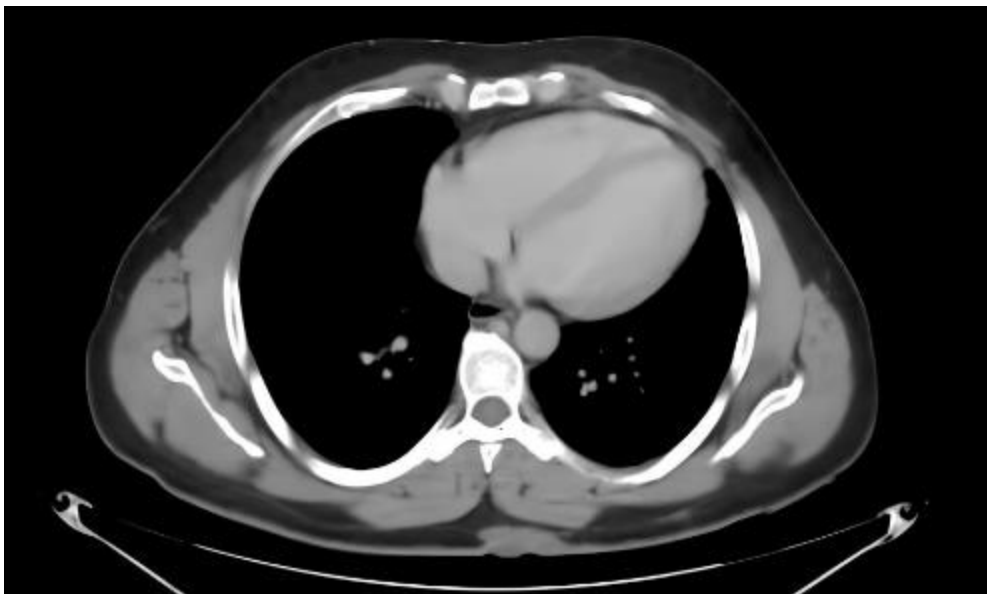


Figure 2 Pre-treatment Staging Imaging. Axial view from the thoracic CT scan showing the soft-tissue attenuation cutaneous-subcutaneous mass on the posterior thorax, without invasion of the underlying muscular structures

A punch biopsy of the dominant lesion was performed. Histopathological examination revealed a dense dermal lymphoid infiltrate composed of a mixture of centrocytes and numerous centroblasts, compatible with a follicular growth pattern. Immunohistochemistry was positive for CD20, CD10, and BCL6, with a markedly elevated proliferative index (Ki-67 >70%), leading to the diagnosis of primary cutaneous follicle center lymphoma, high-grade [1, 2].

The staging work-up included a contrast-enhanced thoraco-abdomino-pelvic computed tomography (CT) scan, which confirmed the cutaneous-subcutaneous mass without evidence of deep tissue invasion or visceral involvement (Figure 2). A few small axillary lymph nodes (<1 cm) were noted but deemed non-specific. To definitively exclude regional nodal disease, a comprehensive ultrasound of all peripheral lymph node basins was performed. This confirmed the absence of any lymph nodes with suspicious morphological features, the largest measuring only 4 mm in the short axis.

Laboratory investigations, including complete blood count, lactate dehydrogenase (LDH), and beta-2-microglobulin, were within normal limits, and Borrelia serology was negative. A final stage of T2aN0M0 was assigned according to the TNM classification for cutaneous lymphomas [7].

The case was reviewed at a multidisciplinary lymphoma tumor board. Given the confirmed localized nature of this high-grade lesion, definitive local radiotherapy with curative intent was recommended. The goal was to achieve durable local control while minimizing toxicity and preserving future treatment options [8].

For treatment planning, the patient was positioned prone on a CT simulator. Careful immobilization was ensured using a knee rest and a headrest, and the treatment fields were marked on the skin (Figure 3).

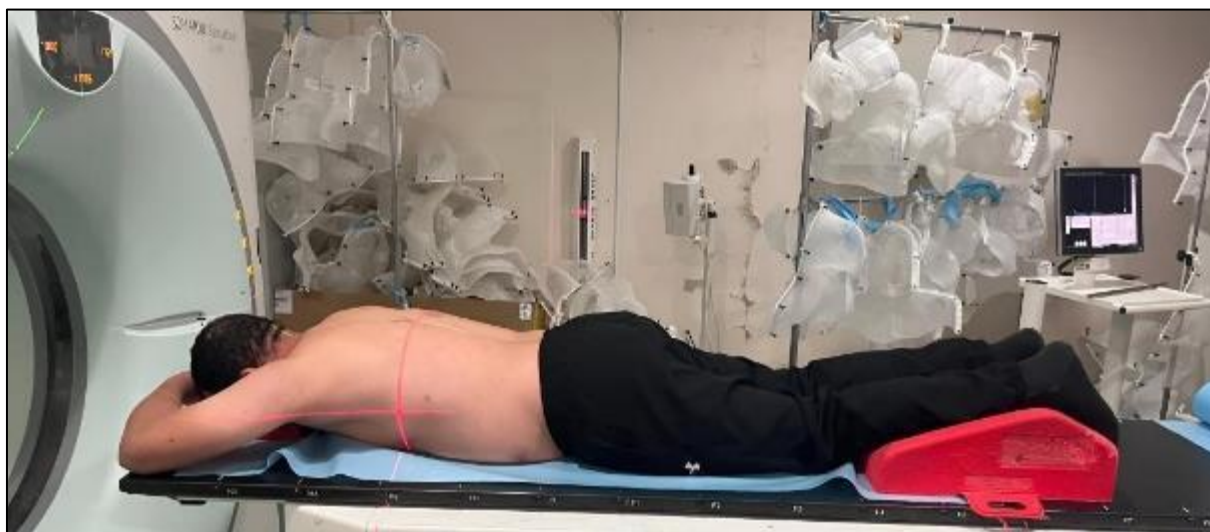

Figure 3 Patient Setup for Simulation. Photograph of the patient positioned prone on the CT simulation table. Immobilization is provided by a knee rest and a headrest. Skin marks and the central positioning laser delineate the area to be treated

The gross tumor volume (GTV) was delineated to encompass all visible and palpable disease. The clinical target volume (CTV) was created by adding a 0.5-cm margin to the GTV along the skin surface to account for potential microscopic extension within the dermal lymphatic network. A further 0.5-cm expansion generated the planning target volume (PTV) to accommodate setup uncertainties.

A three-dimensional conformal radiotherapy (3D-CRT) plan was developed using two opposing tangential photon beams directed at the skin of the back. This technique was selected for its simplicity, excellent dose conformity for superficial targets, and effective sparing of the underlying lungs and spinal cord. The prescribed dose was 40 Gy delivered in 20 fractions of 2 Gy each, prescribed to the ICRU reference point within the PTV, in accordance with International Lymphoma Radiation Oncology Group (ILROG) guidelines for high-grade cutaneous lymphomas [5]. Dosimetric optimization was performed to ensure target coverage while respecting organ-at-risk constraints. The resulting dose distribution demonstrated homogeneous coverage of the PTV with a rapid dose fall-off beyond the target volume. Corresponding dose-volume histogram (DVH) analysis confirmed that 95% of the PTV received the prescribed dose, while dose constraints for organs at risk were met (spinal cord, lungs).

Treatment was delivered daily over four weeks. The patient developed mild, Grade 1 (CTCAE v5.0) radiation dermatitis, characterized by faint erythema and dry desquamation within the treatment field, which was managed effectively with topical emollients. The treatment course was completed without interruption.

The patient was evaluated three months after completing radiotherapy. Clinical examination revealed complete resolution of the initial tumor and plaques. The treated area presented with a flat, atrophic scar and a "cigarette-paper" wrinkling appearance, consistent with expected post-radiotherapy changes, with no induration or residual erythema suggestive of active disease (Figure 4).

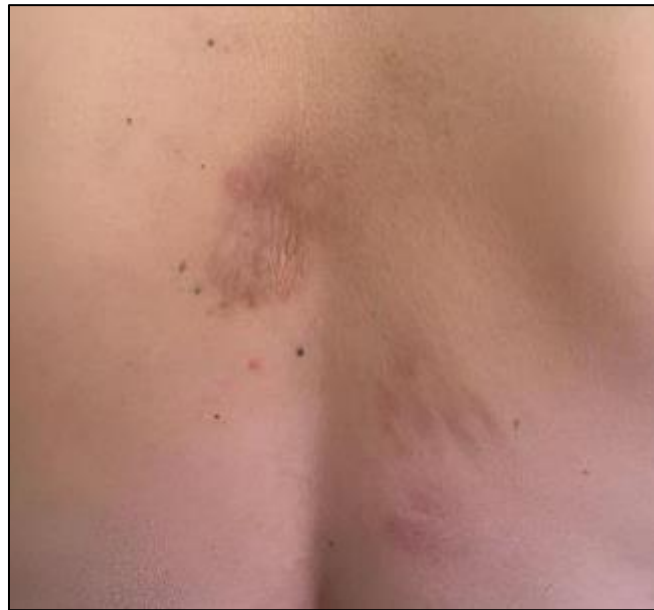

Figure 4 Post-Treatment Clinical Outcome. Photograph taken at the 3- month follow-up visit showing the treated site. The tumor has completely regressed, leaving a flat, atrophic, and finely wrinkled scar

A follow-up CT scan demonstrated a marked reduction in the size and thickness of the treated cutaneous-subcutaneous lesion, confirming an excellent radiologic response (Figure 5). The patient reported no pain or functional limitations. To date, the skin remains in complete clinical remission, and the patient maintains an excellent quality of life.

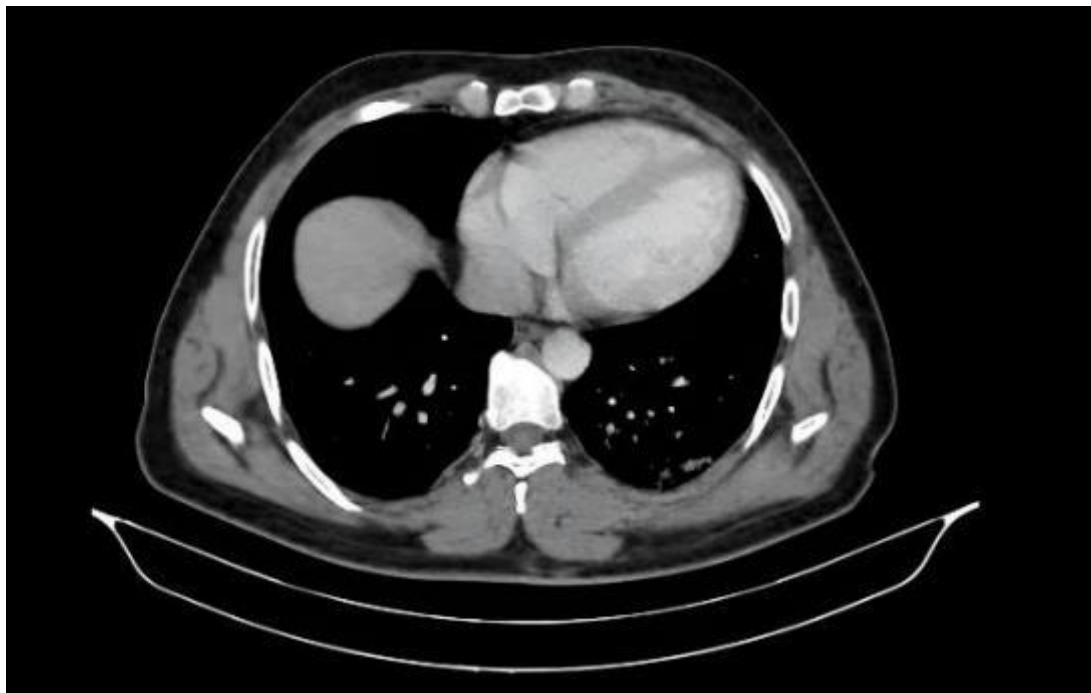


Figure 5 Post-Treatment Radiologic Response. Follow-up axial CT image demonstrating significant regression of the previously noted cutaneous-subcutaneous lesion, corresponding to a very good response

3. Discussion

This case of a high-grade primary cutaneous follicle center lymphoma (PCFCL) successfully treated with definitive 3D-CRT offers a compelling illustration of precision radiotherapy as a cornerstone of management for localized, aggressive cutaneous B-cell lymphomas. This case highlights the evolving diagnostic landscape, where the 2018 WHO-EORTC classification provides crucial clarity in distinguishing PCFCL from other cutaneous B-cell lymphomas, such as the more aggressive diffuse large B-cell lymphoma, leg type, which carries a different prognosis and might influence therapeutic intensity [1]. The integration of immunohistochemical markers like BCL6 and CD10, along with Ki-67, is essential for accurate subtyping and risk stratification.

The importance of accurate staging, including ultrasound evaluation of nodal basins [9], cannot be overstated. The decision to pursue radical radiotherapy as a single modality was guided by the confirmed localized (T2aN0M0) stage and the high-grade histology. For early-stage PCFCL, particularly the less common high-grade variant, radiotherapy is established as the first-line curative treatment, offering superior local control rates exceeding 95% [8]. This approach spares the patient the immediate and long-term toxicities of systemic chemotherapy, which is typically reserved for disseminated disease or transformed lymphoma.

The prescribed dose of 40 Gy in 20 fractions is supported by international consensus guidelines [5]. While lower doses (24-30 Gy) may be sufficient for indolent low-grade subtypes, the high proliferative index (Ki-67>70%) in this case warranted a dose at the higher end of the spectrum to ensure adequate cytoreduction and durable local control for this aggressive histology.

The choice of 3D-CRT over more advanced techniques like intensity-modulated radiotherapy (IMRT) or volumetric arc therapy (VMAT) was deliberate and rational. For superficial targets such as this dorsal cutaneous lesion, a simple tangential 3D-CRT plan provides excellent dose conformity to the PTV with a rapid dose gradient, effectively sparing the underlying lungs and spinal cord. As demonstrated by the dosimetric analysis (V95% > 95%, OAR constraints met), this technique fulfilled all planning objectives. Recent comparative studies affirm that while IMRT can offer modestly improved dose homogeneity for complex volumes, 3D-CRT remains a highly effective, efficient, and accessible standard for straightforward cutaneous targets, minimizing low-dose bath to larger volumes of normal tissue [6]. The excellent clinical outcome-complete response with only Grade 1 dermatitis-validates this approach and aligns with literature reporting minimal toxicity with carefully planned cutaneous irradiation [10].

The observed complete response at 3 months and sustained remission are consistent with the high radioresponsiveness of B-cell lymphomas and confirm the efficacy of this dose-fractionation schedule. This is supported by contemporary systematic reviews [11]. As systemic therapies like immunotherapy and targeted agents continue to advance [12], radiotherapy remains the definitive local modality of choice for such localized presentations. This successful outcome reaffirms the established role of radiation in lymphoma management [13] and is consistent with major clinical guidelines [14].

In conclusion, this report reaffirms that definitive, precisely planned 3D-CRT is a highly effective and well-tolerated curative strategy for localized high-grade PCFCL. It exemplifies a patient-centric model of care where a tailored, precision-focused application of a conventional radiotherapy technique achieves outstanding oncological and functional outcomes, and its role is likely to be further refined through ongoing research into potential dose de-escalation and combination strategies.

4. Conclusion

This case convincingly demonstrates that three-dimensional conformal radiotherapy (3D-CRT), as a precise, accessible, and well-established modality, constitutes the optimal first-line treatment for localized, high-grade primary cutaneous follicle center lymphoma, providing radical and durable local control with a minimal toxicity profile while preserving quality of life. It validates the principle that meticulous planning and adherence to modern dosing recommendations can be as effective as more technologically complex approaches, thereby reinforcing the central role of precision radiotherapy in the therapeutic arsenal for these rare entities before resorting to more burdensome systemic treatments.

Compliance with ethical standards

Disclosure of conflict of interest

The authors declare that they have no conflict of interest.

Statement of informed consent

Written informed consent was obtained from the patient for the publication of this case report and any accompanying images.

Authors' Contributions

All authors contributed to the conception, drafting, and revision of the manuscript.

References

- [1] Willemze R, Cerroni L, Kempf W, et al.: The 2018 update of the WHO-EORTC classification for primary cutaneous lymphomas. *Blood*. 2019, 133:1703-1714. 10.1182/blood-2018-11-881268
- [2] Grange F, Beylot-Barry M, Courville P, et al.: Primary cutaneous diffuse large B-cell lymphoma, leg type and other rare aggressive B-cell lymphomas: A French cutaneous lymphoma study group prognostic study. *J Am Acad Dermatol*. 2018, 78:1195-1202. 10.1016/j.jaad.2018.01.043
- [3] Senff NJ, Noordijk EM, Kim YH, et al.: European Organization for Research and Treatment of Cancer and International Society for Cutaneous Lymphoma consensus recommendations for the management of cutaneous B-cell lymphomas. *Blood*. 2008, 112:1600-1609. 10.1182/blood-2008-04-152850
- [4] Smith BD, Wilson LD, Kacinski BM: Radiation therapy for primary cutaneous B-cell lymphoma: A review of the Stanford experience. *Pract Radiat Oncol*. 2020, 10:93-99. 10.1016/j.prro.2019.09.001
- [5] Specht L, Dabaja B, Illidge T, et al.: Modern radiation therapy for primary cutaneous lymphomas: field and dose guidelines from the International Lymphoma Radiation Oncology Group. *Int J Radiat Oncol Biol Phys*. 2015, 92:32-39. 10.1016/j.ijrobp.2015.01.008
- [6] Kirova YM, Hijal T, Campana F, et al.: Radiotherapy in the management of cutaneous B-cell lymphomas: Clinical and dosimetric study of IMRT versus 3D-CRT. *Cancer Radiother*. 2019, 23:421-426. 10.1016/j.canrad.2019.02.009
- [7] Kim YH, Willemze R, Pimpinelli N, et al.: TNM classification system for primary cutaneous lymphomas other than mycosis fungoides and Sézary syndrome: a proposal of the International Society for Cutaneous Lymphomas (ISCL) and the Cutaneous Lymphoma Task Force of the European Organization of Research and Treatment of Cancer (EORTC). *Blood*. 2007, 110:479-484. 10.1182/blood-2006-12-065672
- [8] Smith BD, Smith GL, Cooper DL, et al.: The effectiveness of radiation therapy for early-stage primary cutaneous B-cell lymphoma: A systematic review and meta-analysis. *J Am Acad Dermatol*. 2021, 84:135-143. 10.1016/j.jaad.2020.08.044
- [9] Virós Amor A, Garces JR, Estrach Panella T, et al.: Role of ultrasound in the staging and follow-up of patients with primary cutaneous lymphoma: A systematic review. *Br J Dermatol*. 2020, 183:1018-1028. 10.1111/bjd.18964
- [10] Hecht M, Hadi HI, Kriz J, et al.: Radiotherapy for primary cutaneous follicle center lymphoma: A multicenter retrospective study of the German Radiation Oncology Group (DEGRO). *Strahlenther Onkol*. 2022, 198:543-551. 10.1007/s00066-021-01869-z
- [11] Michielin O, Zaman K, Rimmer A, et al.: Clinical activity and safety of radioimmunotherapy and radiotherapy in primary cutaneous B-cell lymphomas: A systematic review. *Clin Lymphoma Myeloma Leuk*. 2020, 20:54-64. 10.1016/j.clml.2019.10.016
- [12] Porcu P, Baiocchi RA, Dearden C, et al.: Future directions in the treatment of primary cutaneous B-cell lymphomas: The role of immunotherapy and targeted agents. *Hematol Oncol Clin North Am*. 2020, 34:213-228. 10.1016/j.hoc.2019.08.014
- [13] Yahalom J, Illidge T, Specht L. The role of radiation therapy in patients with Hodgkin or Non-Hodgkin lymphomas. In: Halperin EC, Wazer DE, Perez CA, Brady LW, editors. *Perez and Brady's Principles and Practice of Radiation Oncology*. Philadelphia, PA: Lippincott Williams & Wilkins; 2018. p. 1543.
- [14] National Comprehensive Cancer Network (NCCN). NCCN Clinical Practice Guidelines in Oncology: Primary Cutaneous B-Cell Lymphomas. Version 2.2023. Internet. 2023202430,