



(CASE REPORT)



Rare Infantile Furunculosis in a 3-Month-Old Infant: A Diagnostic Challenge

Houda El Abbade *, Sara Elloudi, Aymane Zaim, Zakia Douhi, Meryem soughi, Hanane Baybay and Fatima Zahra Mernissi

Department of Dermatology of Hassan II university Hospital, Fez, Morocco.

World Journal of Advanced Research and Reviews, 2026, 30(02), 2605-2611

Publication history: Received on 10 April 2026; revised on 20 May 2026; accepted on 22 May 2026

Article DOI: <https://doi.org/10.30574/wjarr.2026.30.2.1453>

Abstract

Staphylococcus aureus is a major pathogen responsible for a wide range of skin and soft tissue infections, including impetigo, folliculitis, furunculosis, and abscesses.

We report the case of a 3-month-old infant with a history of prematurity, cesarean delivery, and neonatal pulmonary infection, presenting with erythematous violaceous nodules on the trunk and back, complicated by a cutaneous abscess. The diagnosis of furunculosis was made based on clinical findings and evolution, with favorable outcome under local care and intravenous antibiotics.

This case is notable due to the rarity of furunculosis in infants, underscoring the importance of including it in the differential diagnosis of suppurative nodular lesions such as impetigo, abscesses, and panniculitis. It also highlights the necessity of systematically investigating predisposing factors, including prematurity and neonatal infectious history.

Early recognition and prompt management of bacterial skin infections in infants are essential to ensure accurate diagnosis, appropriate treatment, and optimal outcomes.

Keywords: Infantile Furunculosis; Infant; Rare Infection; Differential Diagnosis

1. Introduction

Bacterial skin and soft tissue infections are common in infants and children, ranging from superficial infections such as impetigo to deeper infections including furuncles and abscesses [1]. However, furuncle formation in infancy remains exceptionally rare and is only sporadically reported in the literature, often in isolated case reports or in association with specific predisposing factors. This rarity is also indirectly highlighted in older dermatological studies describing "multiple sweat gland abscesses of infants," conditions that may clinically mimic or be confused with furunculosis in early childhood [2].

We report the case of a 3-month-old infant presenting with multiple furuncles complicated by abscess formation, highlighting the diagnostic challenges, differential diagnoses, associated risk factors, and favorable outcome.

2. Case Presentation

A 3-month-old male infant, the fourth child of a four-sibling family, with a history of preterm birth at 32 weeks via cesarean section from an otherwise well-monitored pregnancy, was admitted. His neonatal history was notable for

* Corresponding author: Houda El Abbade

hospitalization in the neonatal intensive care unit due to respiratory distress secondary to pulmonary immaturity and a neonatal urinary tract infection. His twin brother had also been hospitalized for a neonatal infection.

The patient was referred to the pediatric emergency department for erythematous indurated skin lesions evolving over the past 5 days. The history of the illness began 5 days prior with the onset of a raised erythematous lesion on the neck, for which the mother applied an unspecified zinc-copper cream without improvement. Four days later, the lesion progressed with extension of erythema and transformation into a fluctuant lesion with purulent discharge. Subsequently, similar lesions appeared on the neck, nape, and occipital scalp.

Laboratory investigations revealed normocytic normochromic anemia (hemoglobin 9.6 g/dL), leukocytosis ($19,910/\text{mm}^3$) with neutrophil predominance ($10,154/\text{mm}^3$), and elevated C-reactive protein (138.4 mg/L). Serum albumin was normal (37 g/L). Total protein was slightly decreased (62 g/L). Renal and hepatic functions were within normal limits, and serum calcium was normal (10.3 mg/dL). No central venous catheter was present.

The mother reported a history of fever preceding the skin lesions. The infant had received routine vaccinations 5 days prior (oral polio vaccine, pneumococcal vaccine, rotavirus vaccine, and pentavalent vaccine: DTP-Hib-HBV). There was no history of recurrent infections or immunodeficiency. The overall condition evolved in the context of fever but with preserved general status.

Dermatological examination (Figure 1) revealed multiple erythematous inflammatory nodules of variable size on the back (Figure 1a), some of which were surmounted by pustules on the nape of the neck (Figure 1b). In addition, a well-demarcated, warm erythematous indurated plaque was observed on the lateral aspect of the neck, with fluctuance and a central fistulous opening draining purulent material upon pressure (Figure 1c). Other pustular lesions were also noted (Figure 1d), along with non-follicular papules and pustules involving the scalp (Figure 1e). Bilateral inguinal intertrigo was also present (Figure 1f). Mucosal examination was unremarkable.

The main diagnostic hypotheses included: complicated impetigo, complicated varicella, subcutaneous fat necrosis of the newborn and infantile furunculosis

The patient was managed with daily antiseptic baths using mild soap and water, followed by chlorhexidine cleansing of lesions. Topical fusidic acid was applied twice daily. Manual drainage of the cervical abscess through the fistulous opening was performed. Intravenous antibiotics previously initiated by the pediatric team (amoxicillin-clavulanic acid, ciprofloxacin, and metronidazole) were continued.

The clinical course was favorable, with significant improvement in general condition (Figure 2). Partial regression of the nodular lesions on the back was observed (figure 2a), with persistence of a single residual nodule with a pustular component (figure 2b). There was complete resolution of the crusted lesion on the occipital scalp (Figure 2c). A marked regression of the cervical abscess was also noted (figure 2d).

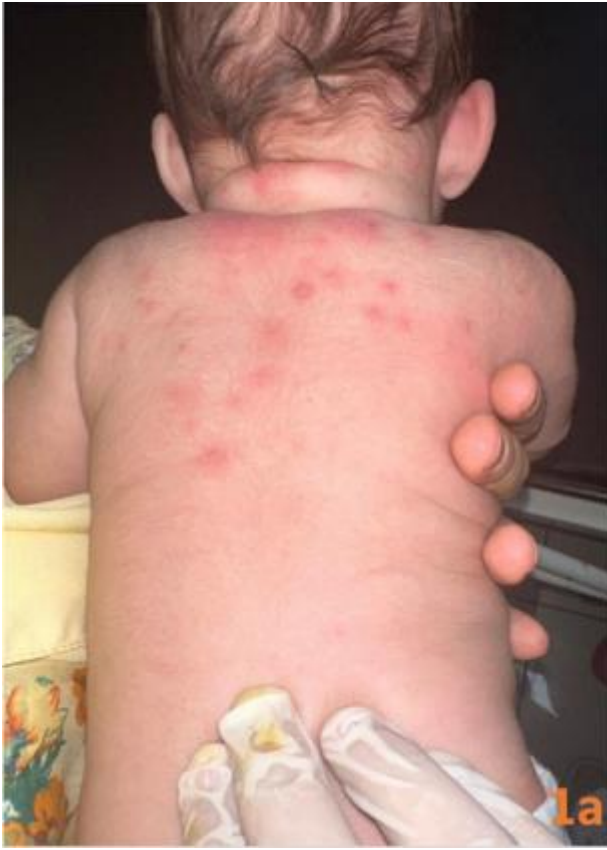

Figure 1a: Multiple erythematous papules and nodules distributed over the back.

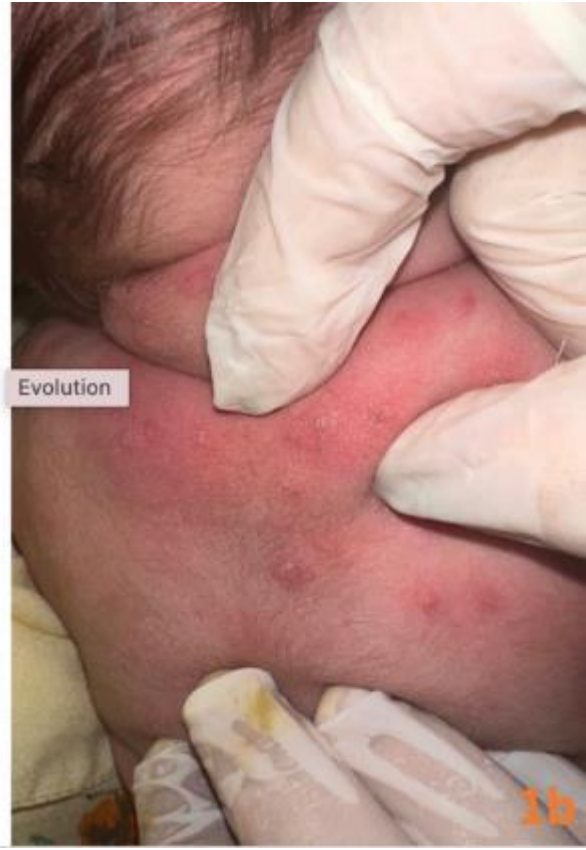

Figure 1b: A 2 cm firm erythematous nodule with a central honey-colored crust.

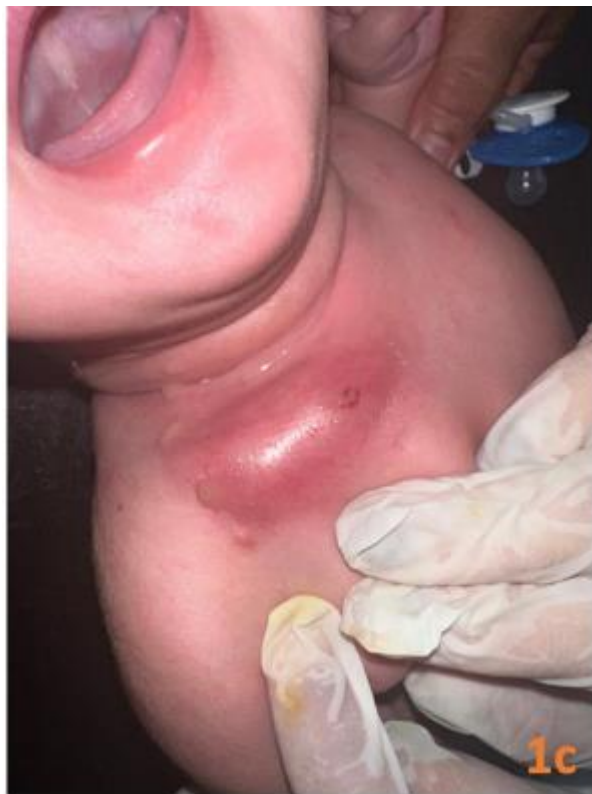

Figure 1c: A 5 cm erythematous, fluctuant swelling with spontaneous purulent discharge on palpation

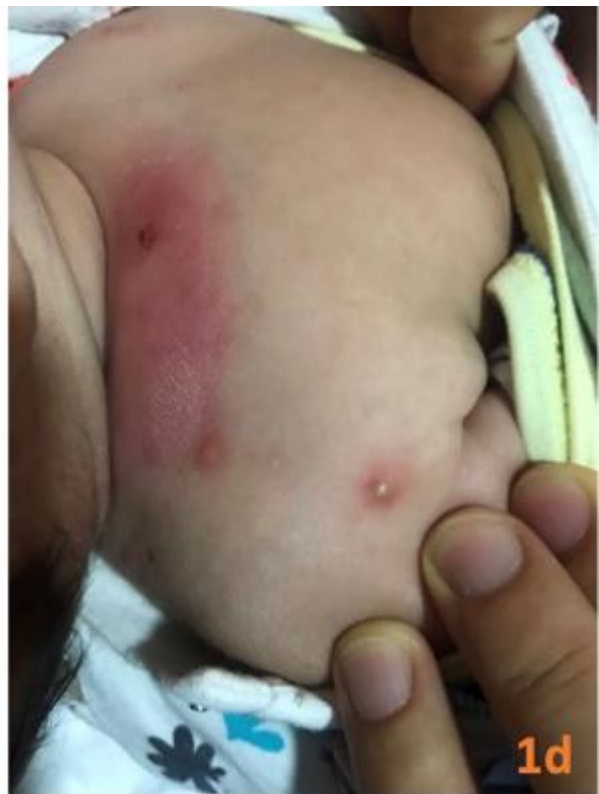

Figure 1d: Erythematous plaque surmounted by a hemorrhagic crust, associated with an isolated pustule below the lesion.

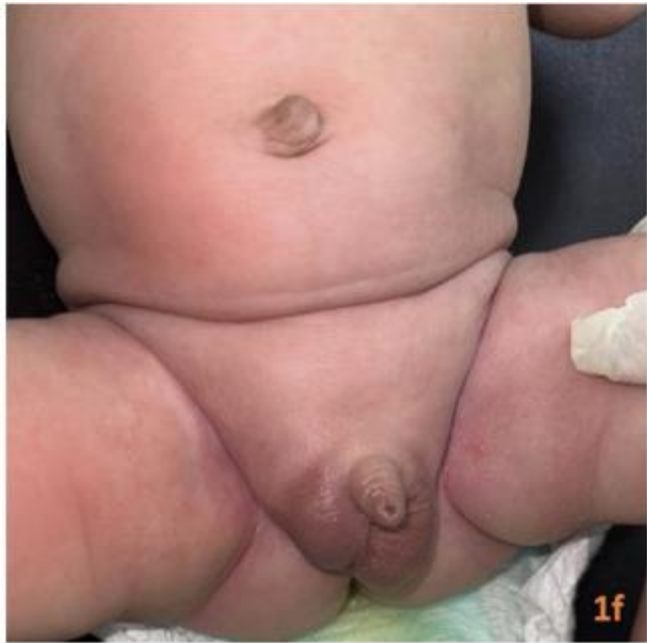
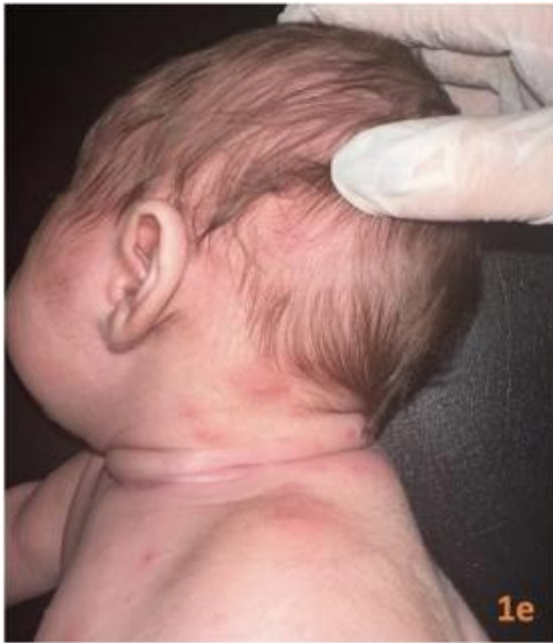
Figure 1e: Erythematous papule on the scalp covered with a crust

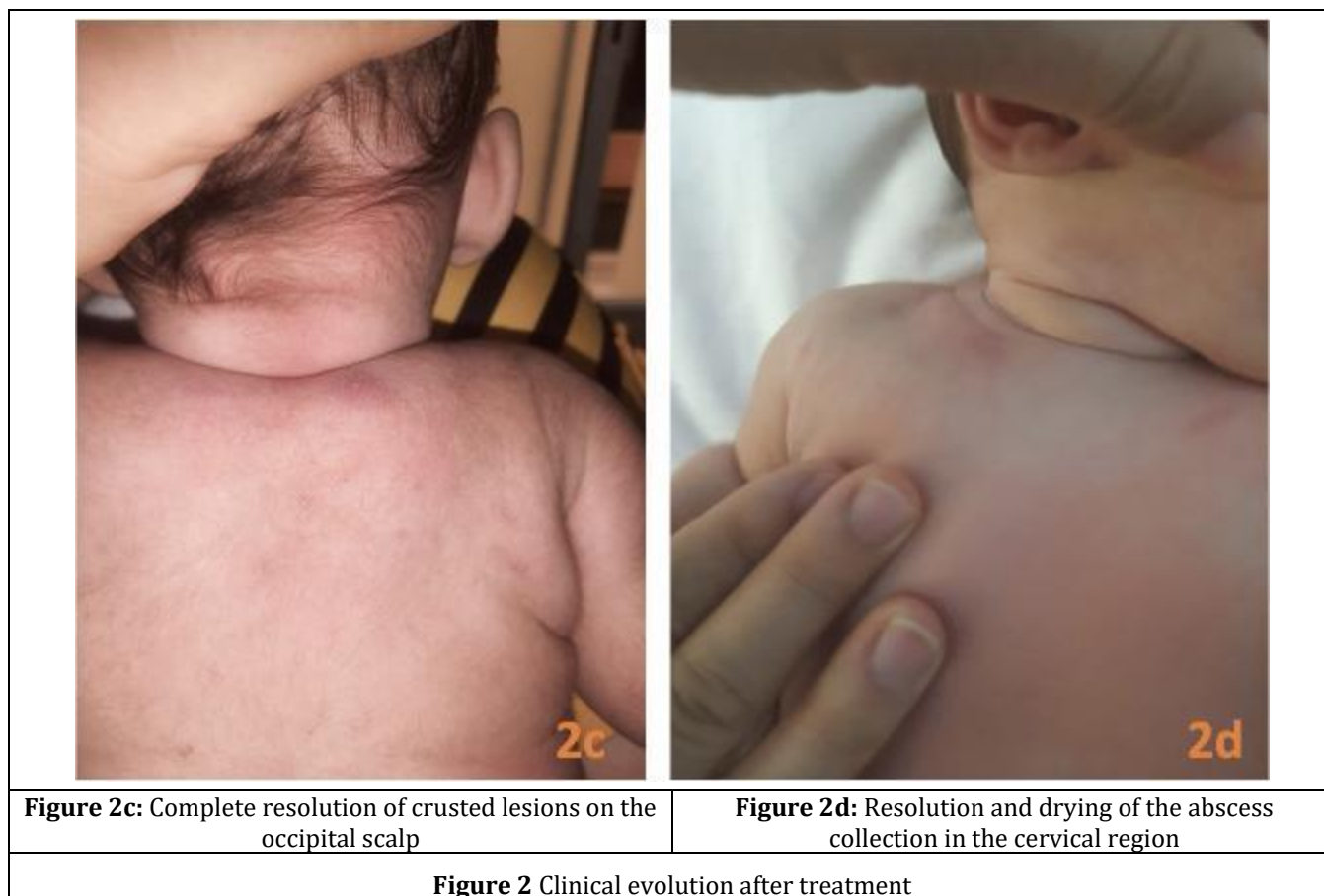
Figure 1f: Bilateral inguinal erythematous plaques with fine desquamation

Figure 1 Initial clinical presentation.

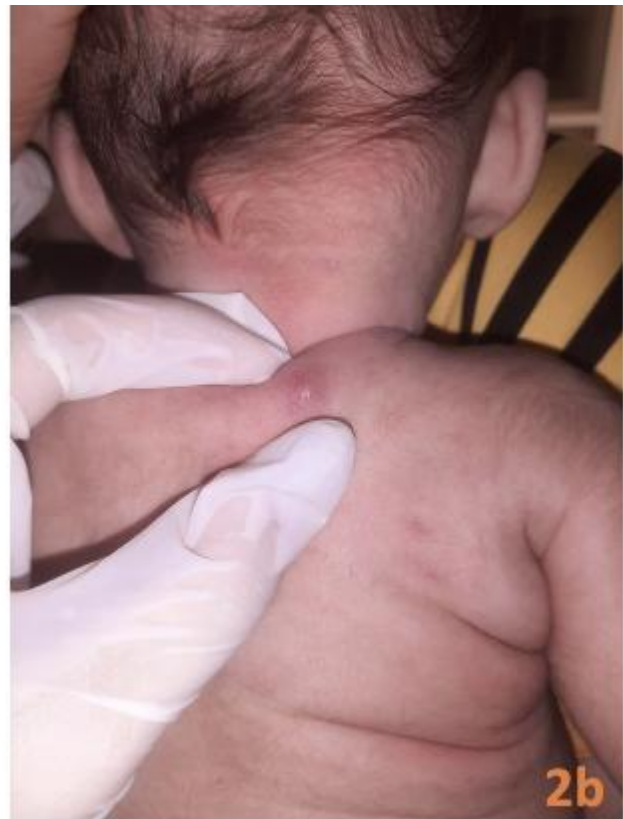
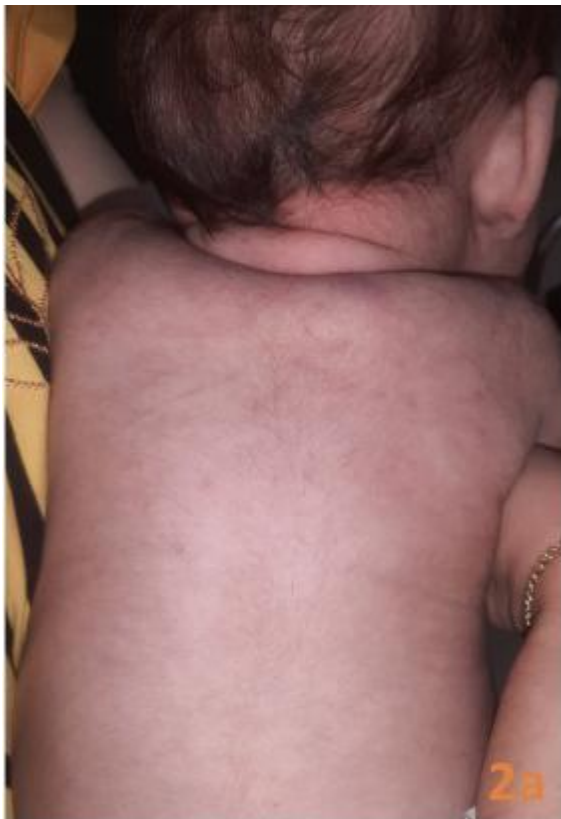
Figure 2a: Near-complete regression of the back lesions

Figure 2b: Persistence of a single small residual nodule with an overlying pustule



3. Discussion

Staphylococcus aureus remains one of the most important and persistent bacterial pathogens responsible for a wide spectrum of skin and soft tissue infections. In children, the most frequently encountered manifestations include impetigo, folliculitis, furuncles, furunculosis, and cutaneous abscesses [1].

Clinically, cutaneous abscesses present as painful or tender nodules that typically become fluctuant within a few days. They may spontaneously drain through a suppurative opening, sometimes associated with necrotic tissue. Abscesses may be primary or secondary, the latter occurring following a breach of the cutaneous barrier. In contrast, furuncles correspond to a deep necrotizing folliculitis caused by *S. aureus*, characterized by a central necrotic core (“core”) and are more frequently described in adults [3].

As in adults, bacterial skin infections in infants are favored by several risk factors, including heat exposure, skin maceration, and direct contact with infected individuals (family members or healthcare personnel) [3]. Additional contributing factors include prior antibiotic exposure, poor hygiene, anemia, and underlying immune deficiencies (congenital or acquired). A history of previous hospitalization may also increase susceptibility [4]. Notably, several of these predisposing factors were identified in our patient.

Finally, the presence of multiple lesions is generally suggestive of complicated or recurrent forms of bacterial skin infection.

The differential diagnosis of infantile furunculosis includes several bacterial infections, notably impetigo, as well as subcutaneous panniculitis such as subcutaneous fat necrosis of the newborn [5].

Impetigo is a superficial epidermal infection most commonly caused by *Staphylococcus aureus* and *Streptococcus pyogenes*. It typically presents as vesicular lesions surrounded by an erythematous halo, which rapidly rupture to form characteristic honey-colored crusts, with a predominance of periorificial involvement [6]. In contrast, furunculosis represents a deeper follicular infection extending into the dermis and subcutaneous tissue [3].

Subcutaneous fat necrosis of the newborn is another important differential diagnosis. It presents with firm, erythematous to violaceous subcutaneous nodules predominantly involving the back, cheeks, buttocks, and limbs. Lesions usually appear within the first days of life and resolve spontaneously over several months. This condition is strongly associated with perinatal risk factors such as prematurity and hypoxic events, particularly secondary to respiratory distress due to pulmonary immaturity. Diagnosis is primarily histological; however, in our patient, biopsy was not performed due to the favorable clinical evolution under appropriate medical management [7].

In our case, the combination of inflammatory nodules with suppuration, the rapid progression of lesions, and the clinical response to antibiotic therapy favored a bacterial origin rather than a panniculitic process.

The management of cutaneous abscesses, furuncles, and carbuncles is primarily based on incision and drainage, which remains the cornerstone of treatment. In most uncomplicated cases, systemic antibiotics are not required. However, antibiotic therapy should be considered in patients with severe immunodeficiency, systemic signs of infection, or associated complications [8].

In our case, the presence of fever, clinical features suggestive of sepsis, and a markedly elevated C-reactive protein justified the use of systemic antibiotic treatment.

In bacterial skin and soft tissue infections, coverage against methicillin-resistant *Staphylococcus aureus* (MRSA) should be considered, particularly in cases with poor clinical response to initial empirical therapy or in the presence of risk factors for resistant organisms [9,10].

4. Conclusion

Infantile furunculosis is an uncommon presentation in early infancy, and may represent a diagnostic challenge due to its clinical overlap with other suppurative and inflammatory skin conditions. This case emphasizes the importance of considering this entity in the differential diagnosis of nodular and abscess-forming skin lesions in young infants, particularly in the presence of predisposing factors such as prematurity and neonatal infections. Early recognition, combined with appropriate antimicrobial therapy and local care, is essential to ensure favorable clinical outcomes and to prevent complications.

Compliance with ethical standards

Disclosure of conflict of interest

No conflict of interest to be disclosed.

Statement of ethical approval

The present research work does not contain any studies performed on human subjects by any of the authors.

Statement of informed consent

Informed consent was obtained from all individual participants included in the study.

References

- [1] Sosa N, et al. Pediatric skin and soft tissue infections: clinical patterns and management. *Journal of Pediatric Infection*. 2019. doi:10.1016/j.jpedinf.2019.01.014 <https://www.sciencedirect.com/science/article/abs/pii/S0149291819300141>
- [2] Arnáiz-García AM, Arnáiz-García ME, Arnáiz J. Management of furuncle, furunculosis and anthrax. *Med Clin (Barc)*. 2015;144(8):376-378. doi: 10.1016/j.medcli.2014.10.023. <https://pubmed.ncbi.nlm.nih.gov/25579772/>
- [3] Coutinho I, et al. Community-acquired MRSA skin infections. *Clinical and Cosmetic Investigational Dermatology*. 2014;7:59-66. doi:10.2147/CCID.S393459 <https://pmc.ncbi.nlm.nih.gov/articles/PMC3934592/>

- [4] Ibler KS, Kromann CB. Recurrent furunculosis-challenges and management: a review. *Clin Cosmet Investig Dermatol.* 2014;7:59-64. doi:10.2147/CCID.S35302. <http://pmc.ncbi.nlm.nih.gov/articles/PMC3934592/pdf/ccid-7-059>.
- [5] Zaroni RD, Rodrigues ACP, Bosch AL, Nery DL, Maia DC, Gonçalves FKS, et al. Impetigo infantil: a comprehensive review of dermatological and pediatric considerations. *Brazilian Journal Implantology and Health Sciences.* 2023;5(5):1817-1828. doi:10.36557/2674-8169.2023v5n5p1817-1828. Available from: <https://www.researchgate.net/publication/375064087>
- [6] Sullivan JR, et al. Bacterial skin and soft tissue infections. *Brazilian Annals of Dermatology.* 2013;88(6 Suppl 1):154–165. doi:10.1590/abd1806-4841.20132206 Available from: <https://pmc.ncbi.nlm.nih.gov/articles/PMC3875964/>
- [7] Stevens DL, et al. Practice guidelines for skin and soft tissue infections. *Infectious Diseases Society of America.* 2014. doi:10.1093/cid/ciu296 Pages: e10–e52 Available from: <https://www.idsociety.org/practice-guideline/skin-and-soft-tissue-infections/>
- [8] Linz Ms, Mattappallil A, Finkel D, Parker D. Antibiotics for skin and soft tissue infections: mechanisms and clinical use. *Antibiotics (Basel).* 2023;12(5):557. doi:10.3390/antibiotics12050557 Available from: <https://pmc.ncbi.nlm.nih.gov/articles/PMC10044708/>
- [9] Zha M, Usatine R. Common skin conditions in children and adolescents: bacterial infections. *FP Essent.* 2024;542:11-18. PMID:38896826. <https://pubmed.ncbi.nlm.nih.gov/38896826/>
- [10] Nguyen-Huu CD, Cao TN, Nguyen VT. Clinical characteristics and treatment outcomes of pediatric bacterial skin and soft tissue infections in Central Vietnam: a prospective study. *Global Pediatric Health.* 2024;11:2333794X241283785. doi:10.1177/2333794X241283785. Available from: <https://pubmed.ncbi.nlm.nih.gov/39315057/>