

Sarcomatoid carcinoma of the submandibular gland: A rare and aggressive salivary malignancy

A.Adriuach ^{1,*}, R.Borki ^{1,2,3}, S. El Aissaoui ¹, H. Dehane ¹, H. Mimouni ^{1,2} and I.Rkain ^{1,2}

¹ Department of ENT, Mohammed VI University hospital, Tangier.

² Faculty of medicine and pharmacy, Abdelmalik Essaadi University, Tangier, Morocco.

³ Anatomy laboratory, Abdelmalik Essaadi University, Tangier, Morocco.

World Journal of Advanced Research and Reviews, 2026, 30(02), 1620-1626

Publication history: Received on 11 April 2026; revised on 16 May 2026; accepted on 19 May 2026

Article DOI: <https://doi.org/10.30574/wjarr.2026.30.2.1414>

Abstract

Sarcomatoid carcinoma is an uncommon and aggressive malignancy characterized by mixed epithelial and mesenchymal features. Its occurrence in the salivary glands is extremely rare, particularly in the submandibular gland, where only a limited number of cases have been described. Because of this rarity, the clinical presentation, prognosis, and optimal management remain insufficiently defined.

We report the case of a 62-year-old patient who presented with a right submandibular swelling that progressively increased in size. The patient underwent wide surgical excision of the lesion. Histopathological examination confirmed the diagnosis of sarcomatoid carcinoma. Adjuvant radiotherapy was administered as part of the postoperative management.

This case highlights the diagnostic challenge and therapeutic considerations associated with this rare tumor. Early recognition and multidisciplinary management are essential. Additional case reports are needed to better understand the biological behavior and improve treatment strategies for this uncommon malignancy

Keywords: Sarcomatoid carcinoma; Submandibular gland; Salivary gland malignancy; TTF-1

1. Introduction

Sarcomatoid carcinoma is a rare and highly aggressive biphasic malignancy characterized by the coexistence of epithelial and spindle-cell mesenchymal components. It is most commonly described in the upper aerodigestive tract, lungs, and other visceral organs, whereas involvement of the salivary glands remains exceptionally uncommon. Among salivary gland locations, the submandibular gland represents an exceedingly rare site, with only a few cases reported in the literature. Owing to its rarity and histopathological heterogeneity, the diagnosis of sarcomatoid carcinoma is often challenging and requires careful morphological and immunohistochemical evaluation to differentiate it from other spindle-cell neoplasms, including true sarcomas and carcinosarcomas. Clinically, these tumors are characterized by aggressive behavior, rapid local progression, and a poor prognosis. Because no standardized therapeutic guidelines currently exist, management is generally based on a multidisciplinary approach combining radical surgical excision with adjuvant radiotherapy and, in selected cases, chemotherapy. Reporting additional cases is essential to improve understanding of the clinicopathological features, biological behavior, and optimal therapeutic strategies for this uncommon malignancy. We herein report a rare case of sarcomatoid carcinoma arising in the submandibular gland in a 62-year-old patient managed with surgery followed by postoperative chemotherapy and radiotherapy.

* Corresponding author: A.Adriuach

2. Case report

A 62 year old male with a past medical history of type 2 diabetes mellitus presented with a right submandibular swelling.

The swelling first appeared approximately eight months prior to admission. The patient initially consulted a general practitioner and received oral antibiotic therapy. Due to the lack of sustained clinical improvement, he was referred to our department for further diagnostic evaluation and management.

The swelling progressively increased in size. The clinical course was associated with deterioration of the general condition, including unintentional weight loss estimated at 10 kg over two months. The patient denied fever, night sweats, or respiratory symptoms.

On physical examination, a large right submandibular mass was noted, causing visible cervical asymmetry. The swelling appeared well-defined, protruding, and tense, with stretched overlying skin. The skin showed mild discoloration without ulceration or inflammatory signs (Figure 1).

On palpation, the mass was firm, non-tender, and fixed to both superficial and deep planes. No cutaneous fistula or discharge was observed. No clinically palpable cervical lymphadenopathy was detected. The remainder of the head and neck examination was unremarkable.

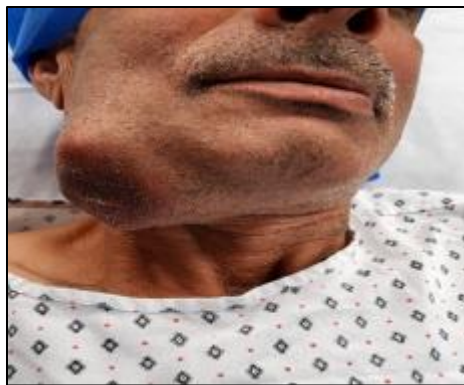

Figure 1 Clinical aspect of the right submandibular mass at presentation

Initial cervical ultrasound revealed a right submandibular mass suggestive of lymphadenopathy, with differential diagnoses including infectious lymphadenitis, particularly tuberculosis, and hematologic malignancy.

Contrast-enhanced cervical CT demonstrated a large heterogeneous right submandibular mass with central necrotic areas associated with ipsilateral cervical lymph nodes (Figure 2).

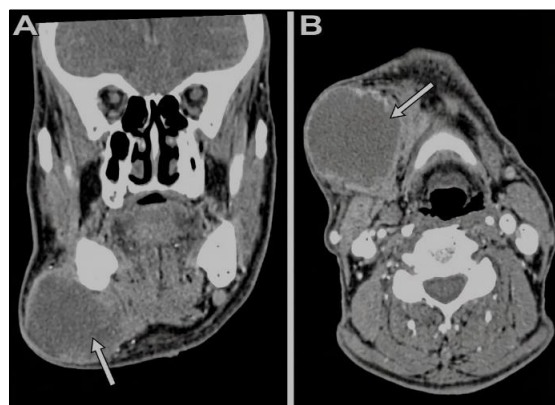


Figure 2 Cervical Contrast-Enhanced Computed Tomography (CT) Scan. (A) Coronal view and (B) Axial view demonstrating a large, well-defined, and heterogeneously enhancing mass originating from the right submandibular gland (white arrow)

Biopsy with immunohistochemical analysis revealed features consistent with sarcomatoid carcinoma. Based on radiological and pathological correlation, a primary salivary gland origin was considered most likely.

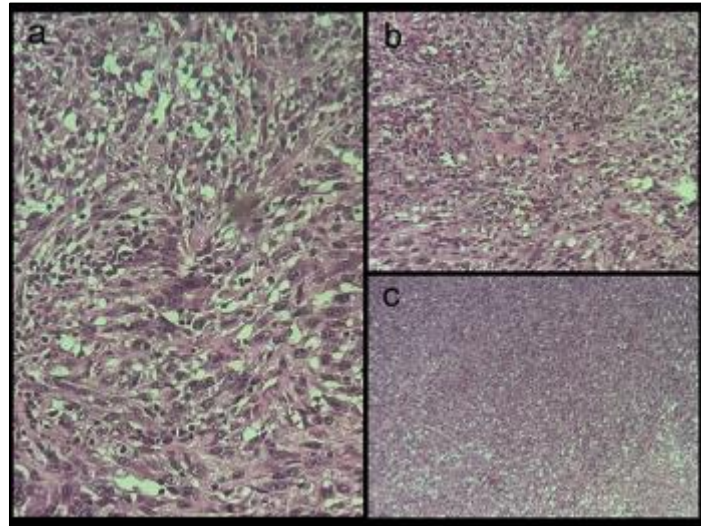


Figure 3 Hematoxylin–eosin sections showing a biphasic malignant tumor of the submandibular gland consistent with carcinosarcoma. (a) High power ($\times 400$) demonstrating marked spindle-cell pleomorphism with scattered atypical epithelioid cells. (b) Intermediate power ($\times 200$) highlighting intimate admixture and transition between carcinomatous and sarcomatous components. (c) Low power ($\times 100$) showing an infiltrative, poorly circumscribed tumor replacing normal salivary gland architecture

Metabolic imaging using ^{18}F -FDG PET/CT confirmed a hypermetabolic tumoral process of the right submandibular gland. Cervical lymph nodes with suspicious metabolic activity were identified, predominantly located ipsilateral to the primary tumor (Figure4).

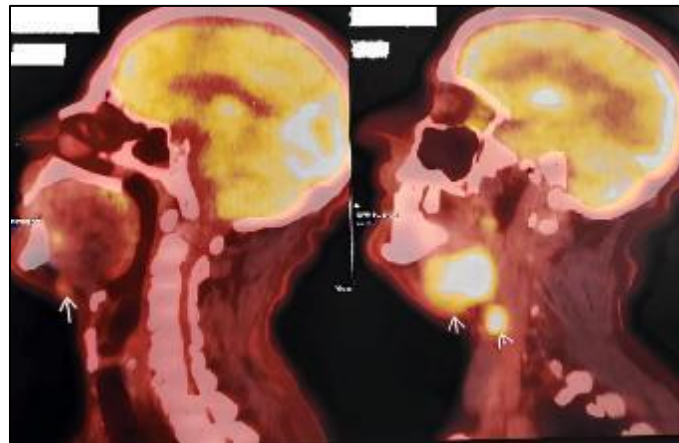


Figure 4 Coronal fused PET-CT images demonstrating an intensely hypermetabolic lesion in the left submandibular region, consistent with the primary tumor, with adjacent hypermetabolic cervical lymphadenopathy

No metabolic abnormalities suggestive of distant metastatic disease were identified. (Figure 5).

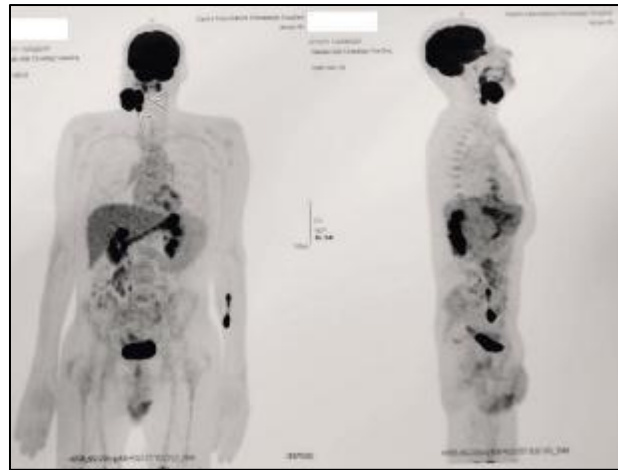


Figure 5 Whole-body FDG PET/CT maximum intensity projection (MIP) images (anterior and lateral views) demonstrating a focal area of intense hypermetabolic activity in the left submandibular region (arrows), corresponding to the known primary lesion. No abnormal FDG uptake is identified elsewhere to suggest a distant primary tumor or metastatic disease. Physiological uptake is noted in the brain, liver, kidneys, and urinary bladder

Following multidisciplinary tumor board discussion, the patient underwent wide surgical excision of the tumor with right neck dissection (Figure 6) followed by adjuvant chemotherapy and radiotherapy.

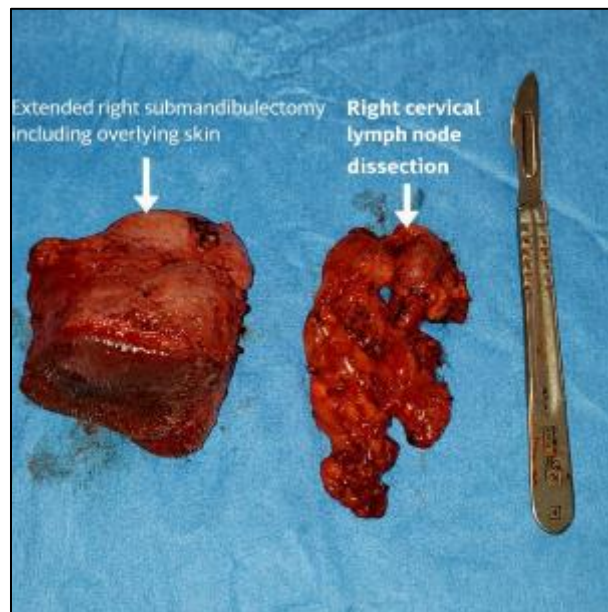


Figure 6 Surgical specimen after extended right submandibulectomy and right cervical lymph node dissection

On follow up after a period of 2 years, no evidence of tumor recurrence was observed.

3. Discussion

Primary sarcomatoid carcinoma of the submandibular gland is exceptionally rare. Salivary gland cancers account for only a small fraction of head and neck malignancies, and submandibular tumors are far less common than parotid lesions. Within this already limited subgroup, sarcomatoid carcinoma is particularly unusual, which explains why the diagnosis is seldom suspected at first presentation and why the literature is largely confined to isolated reports and small clinicopathologic series [1-6].

The clinical presentation is often concerning but not specific. A progressively enlarging submandibular mass associated with firmness, fixation to deep planes, skin stretching, and constitutional deterioration strongly suggests an aggressive

malignant process. However, these features do not immediately distinguish a primary salivary gland tumor from necrotic cervical lymphadenopathy, metastatic nodal disease from an occult upper aerodigestive tract primary, lymphoma, or chronic infectious disease. This explains why the initial clinical impression may remain broad despite a clearly suspicious lesion [1,6,7].

Imaging is therefore central to the initial assessment. Ultrasound is useful as a first-line investigation because it confirms the presence of a mass and provides an initial evaluation of regional lymph nodes, but in large necrotic lesions it may remain insufficiently specific and can suggest lymphadenopathy rather than a primary glandular tumor. Contrast-enhanced CT is more informative because it better defines tumor heterogeneity, central necrosis, locoregional extension, and nodal involvement, all of which are important for therapeutic planning [7,11,12]. In the present case, CT strongly supported a malignant process but could not definitively establish whether the lesion arose from the submandibular gland or represented nodal disease from another site.

At that stage, the differential diagnosis remains wide. In an older patient presenting with a necrotic submandibular mass and weight loss, infectious or granulomatous adenitis, lymphoma, metastatic nodal disease, and primary submandibular gland carcinoma must all be considered [3,6,7]. One of the difficulties is that aggressive salivary malignancies may clinically and radiologically mimic nodal pathology, especially when the lesion is large and necrotic. For this reason, complete head and neck examination and appropriate cervicothoracic imaging are essential during the initial work-up [3,7].

The choice of tissue sampling is also important. Fine-needle aspiration cytology can be considered as an initial minimally invasive investigation for submandibular masses and remains a standard tool in salivary gland pathology [3,8,9]. Its limitations, however, become more apparent in high-grade tumors with extensive necrosis, marked pleomorphism, or unusual spindle-cell morphology, where cytology may establish malignancy without allowing reliable classification [8,9]. In the present case, biopsy was justified because the lesion was large, clinically aggressive, and radiologically suspicious, and because a larger tissue sample was needed for immunohistochemical characterization before treatment planning. Although fine-needle aspiration could have been proposed initially, core biopsy was more likely to provide diagnostically useful material in this setting [8,9].

The pathologic findings were one of the most distinctive aspects of this case. Sarcomatoid morphology in the head and neck opens a broad differential diagnosis that includes spindle-cell squamous carcinoma, myoepithelial carcinoma, melanoma, and metastatic sarcomatoid tumors, in addition to primary salivary epithelial malignancies [3-5,14]. In this case, CK7 positivity supported epithelial differentiation, while vimentin positivity was compatible with sarcomatoid transformation. The absence of p40, p63, and CK5/6 argued against a conventional squamous phenotype, and negativity for S100 and HMB45 made myoepithelial and melanocytic lesions less likely [3-5]. The most unusual feature was the aberrant TTF-1 positivity. This appropriately raised the possibility of a pulmonary primary, but the lack of Napsin A expression and negative thyroid markers made that interpretation less convincing. TTF-1 is highly sensitive for pulmonary and thyroid tumors, but it is not entirely specific and should not be interpreted in isolation [10].

This immunohistochemical peculiarity directly influenced the extension work-up. In this case, PET/CT was performed after the biopsy findings had raised concern for a possible pulmonary origin, which reflects a logical diagnostic sequence. Once that possibility was considered, staging had two goals: excluding another primary tumor and assessing whether the disease remained amenable to curative treatment. Cervico-thoraco-abdomino-pelvic CT did not reveal any distant primary lesion or metastatic disease, and 18F-FDG PET/CT confirmed a hypermetabolic lesion centered on the right submandibular gland with ipsilateral cervical nodal uptake, without evidence of pulmonary hypermetabolism or distant metastasis [11,12]. In this context, PET/CT was useful not to establish histology, but to clarify the primary site and complete staging.

Treatment should follow the principles used for aggressive salivary gland malignancies. Complete surgical resection remains the cornerstone whenever the disease is resectable [1,2,13]. In the present case, the absence of distant metastasis supported a curative strategy based on wide excision of the primary lesion including overlying skin with ipsilateral neck dissection. Final histopathologic examination of the surgical specimen confirmed primary sarcomatoid carcinoma of the submandibular gland with nodal involvement. These findings supported postoperative adjuvant treatment. Current recommendations favor adjuvant radiotherapy in the presence of adverse features such as high-grade histology, nodal metastasis, advanced local disease, or margin concerns, while chemotherapy may be considered in selected high-risk cases after multidisciplinary discussion [2,13].

Follow-up should remain prolonged and careful. Even when early postoperative evolution is favorable, high-grade salivary gland malignancies retain a meaningful risk of locoregional recurrence and distant dissemination [1,2,6,13].

Early disease control is reassuring, but it does not eliminate the possibility of later relapse. Surveillance should therefore rely on repeated clinical examination, interval cervical imaging according to local practice, and attention to distant symptoms, particularly pulmonary symptoms, given the metastatic potential of aggressive salivary malignancies [1,2,13]. Prognosis more broadly depends on tumor grade, local extension, nodal status, completeness of excision, and response to adjuvant therapy [1,2,6].

4. Conclusion

Sarcomatoid carcinoma of the submandibular gland is a rare and aggressive salivary malignancy that may mimic inflammatory, nodal, or metastatic cervical disease. Diagnosis requires careful integration of clinical findings, imaging, histopathology, and immunohistochemistry, while management relies on complete staging and multimodal treatment planning. In these uncommon tumors, close clinicoradiologic-pathologic correlation remains essential for accurate diagnosis and appropriate management.

Compliance with ethical standards

Disclosure of conflict of interest

Institutional ethical requirements were respected according to local regulations.

Statement of informed consent

Written informed consent was obtained from the patient for publication of this case report and accompanying images

References

- [1] Gilbert MR, Sharma A, Schmitt NC, Johnson JT, Ferris RL, Duvvuri U, et al. A 20-year review of 75 cases of salivary duct carcinoma. *JAMA Otolaryngol Head Neck Surg.* 2016;142(5):489-95.
- [2] van Herpen C, Vander Poorten V, Skalova A, Terhaard C, Maroldi R, van Engen A, et al. Salivary gland cancer: ESMO-EURACAN Clinical Practice Guideline for diagnosis, treatment and follow-up. *ESMO Open.* 2022;7(6):100602.
- [3] Seethala RR, Stenman G. Update from the 5th edition of the World Health Organization Classification of Head and Neck Tumors: salivary glands. *Head Neck Pathol.* 2022;16(1):74-98.
- [4] Nagao T, Gaffey TA, Serizawa H, Iwaya K, Watanabe A, Yoshida T, Yamazaki K, Sageshima M, Lewis JE. Sarcomatoid variant of salivary duct carcinoma: clinicopathologic and immunohistochemical study of eight cases with review of the literature. *Am J Clin Pathol.* 2004 Aug;122(2):222-31.
- [5] Padberg BC, Sasse B, Huber A, Pfaltz M. Sarcomatoid salivary duct carcinoma. *Ann Diagn Pathol.* 2005 Apr;9(2):86-92.
- [6] Steuer CE, Hanna GJ, Viswanathan K, Bates JE, Kaka AS, Schmitt NC, et al. The evolving landscape of salivary gland tumors. *CA Cancer J Clin.* 2023;73(6):597-619.
- [7] Uchihashi T, Kodama S, Sugauchi A, Hiraoka S, Hirose K, Usami Y, et al. Salivary duct carcinoma of the submandibular gland presenting a diagnostic challenge: a case report. *World J Clin Cases.* 2021;9(12):2908-15.
- [8] Rossi ED, Wong LQ, Bizzarro T, Petrone G, Mule A, Fadda G, et al. The impact of FNAC in the management of salivary gland lesions: institutional experiences leading to a risk-based classification scheme. *Cancer Cytopathol.* 2016;124(6):388-96.
- [9] Nagao T. Diagnostic clues and pitfalls in salivary gland fine-needle aspiration cytology: a review. *Semin Diagn Pathol.* 2024;41(4):207-19.
- [10] Möller K, Gulzar T, Lennartz M, Viehweger F, Kluth M, Hube-Magg C, et al. TTF-1 is a highly sensitive but not fully specific marker for pulmonary and thyroidal cancer: a tissue microarray study evaluating more than 17,000 tumors from 152 different tumor entities. *Virchows Arch.* 2024;485(5):815-28.
- [11] Westergaard-Nielsen M, Rohde M, Godballe C, Eriksen JG, Larsen SR, Gerke O, et al. Up-front F18-FDG PET/CT in suspected salivary gland carcinoma. *Ann Nucl Med.* 2019;33(8):554-63.

- [12] Jeong HS, Chung MK, Son YI, Choi JY, Kim HJ, Ko YH, et al. Role of 18F-FDG PET/CT in management of high-grade salivary gland malignancies. *J Nucl Med.* 2007;48(8):1237-44.
- [13] Geiger JL, Ismaila N, Beadle B, Caudell JJ, Chau N, Deschler D, et al. Management of salivary gland malignancy: ASCO guideline. *J Clin Oncol.* 2021;39(17):1909-41.
- [14] Jeong JS, Cho KJ, Kim D, Lee YS, Song JS. Genomic alteration in rare subtype of sarcomatoid salivary duct carcinoma. *Pathol Res Pract.* 2021;228:153678.