

## Pelvic ectopic kidney with ureteropelvic junction obstruction: Surgical management and anatomical challenges: A case report

Marlyatou Diallo\*, Reda Madafar, Rhyan Ouaddane Alami, Mustapha Ahssaini, Soufiane Mellas, Jalal Eddine El Ammari, Mohammed Fadl Tazi and Mohammed Jamal El Fassi

*Department of urology, Hassan II University hospital, Fez, Morocco.*

World Journal of Advanced Research and Reviews, 2026, 30(02), 797-799

Publication history: Received on 25 March 2026; revised on 04 May 2026; accepted on 07 May 2026

Article DOI: <https://doi.org/10.30574/wjarr.2026.30.2.1234>

### Abstract

Ureteropelvic junction obstruction (UPJO) associated with a pelvic ectopic kidney is a rare condition that poses significant diagnostic and surgical challenges due to anatomical variations. We report the case of a 40-year-old male with no significant medical history, presenting with intermittent abdominal and pelvic pain evolving over one year with recent worsening. Imaging revealed a left pelvic ectopic kidney with marked hydronephrosis secondary to UPJO. The patient underwent open dismembered pyeloplasty according to the Anderson-Hynes technique with double J stent placement. The postoperative course was uneventful. UPJO in ectopic pelvic kidneys requires careful preoperative evaluation and individualized surgical planning. Despite the increasing use of minimally invasive techniques, open pyeloplasty remains a reliable and effective option in complex anatomical situations, providing satisfactory functional outcomes.

**Keywords:** Pelvic ectopic kidney; Ureteropelvic junction obstruction; Pyeloplasty; Anderson-Hynes; Hydronephrosis; Urology

### 1. Introduction

Pelvic ectopic kidney is a rare congenital anomaly resulting from abnormal renal ascent during embryogenesis (1,2). Although often asymptomatic, it may be associated with complications such as ureteropelvic junction obstruction (UPJO). The diagnosis and management of UPJO in ectopic kidneys are particularly challenging due to abnormal anatomical relationships and frequent vascular variations. We report a case of UPJO occurring in a pelvic ectopic kidney and discuss its diagnostic and therapeutic particularities.

### 2. Case presentation

A 40-year-old male with no significant past medical history, except for previous surgery for intestinal obstruction, presented with intermittent abdominal and pelvic pain evolving for one year, with recent worsening over the last three months.

Clinical examination revealed a patient in good general condition, afebrile and hemodynamically stable. Abdominal examination showed a midline laparotomy scar with no tenderness.

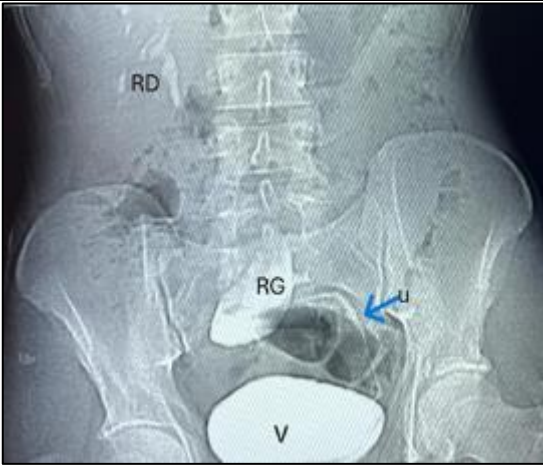
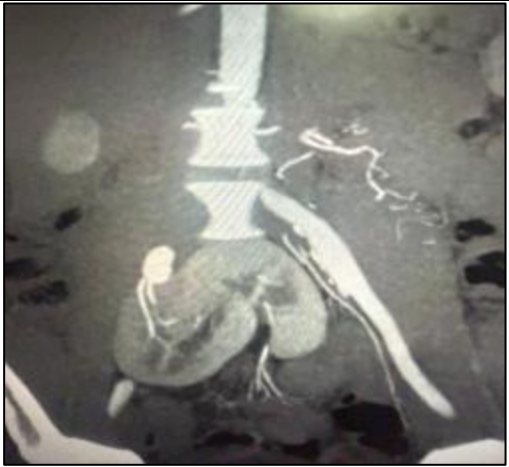
Laboratory findings demonstrated preserved renal function (urea 0.4 g/L, creatinine 7.6 mg/L) and sterile urine culture.

\* Corresponding author: Marlyatou Diallo, Email: [Marlyatou.diallo@usmba.ac.ma](mailto:Marlyatou.diallo@usmba.ac.ma)

Abdominal CT scan revealed a left pelvic ectopic kidney with marked hydronephrosis, with a dilated renal pelvis measuring 82×65 mm, suggestive of ureteropelvic junction obstruction.

Cystography showed no vesicoureteral reflux.

Given the clinical symptoms and radiological findings, surgical management was indicated.


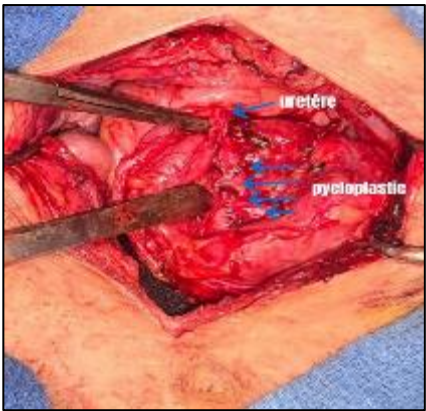
	
<p><b>Figure 1</b> Intravenous urography showing delayed excretion with upstream pyelocaliceal dilatation suggestive of ureteropelvic junction obstruction</p>	<p><b>Figure 2</b> Coronal CT scan showing a left pelvic ectopic kidney with marked hydronephrosis secondary to ureteropelvic junction obstruction</p>

### 2.1. Surgical management

An open surgical approach was chosen due to the anatomical complexity related to the pelvic location of the kidney. After careful exposure and dissection, the stenotic ureteropelvic junction was identified.

A dismembered pyeloplasty according to the Anderson-Hynes technique was performed, involving resection of the stenotic segment followed by ureteropelvic anastomosis. A double J stent was placed to ensure adequate drainage.

The procedure was completed without intraoperative complications.

	
<p><b>Figure 3</b> Intraoperative view showing a stenotic ureteropelvic junction in a pelvic ectopic kidney</p>	<p><b>Figure 4</b> Intraoperative view showing a stenotic ureteropelvic junction in a pelvic ectopic kidney</p>

### 3. Discussion

Pelvic ectopic kidney is a rare congenital anomaly with an estimated incidence ranging from 1 in 2,200 to 1 in 3,000 births. Its association with UPJO is uncommon but clinically significant.

The anatomical variability of ectopic kidneys, including abnormal vascular supply and atypical orientation of the renal pelvis, makes both diagnosis and surgical management challenging (3,4).

Although minimally invasive techniques such as laparoscopy and robotic surgery are increasingly used, open pyeloplasty remains a valuable option in complex cases, particularly when anatomical landmarks are distorted or vascular anomalies are suspected (5).

The Anderson-Hynes dismembered pyeloplasty remains the gold standard, providing excellent functional outcomes and allowing anatomical correction tailored to individual variations (5,6).

Our case highlights the importance of preoperative imaging and individualized surgical planning in achieving optimal outcomes.

Our findings are consistent with previously reported series, which highlight the technical challenges associated with UPJO in ectopic kidneys. However, in our case, the choice of an open approach was primarily driven by the anatomical complexity and the need for optimal exposure, reinforcing the importance of tailoring surgical strategy to individual anatomical variations.

---

#### 4. Conclusion

Pelvic ectopic kidney is a rare congenital anomaly with an estimated incidence ranging from 1 in 2,200 to 1 in 3,000 births. Its association with UPJO is uncommon but clinically significant.

The anatomical variability of ectopic kidneys, including abnormal vascular supply and atypical orientation of the renal pelvis, makes both diagnosis and surgical management challenging.

Although minimally invasive techniques such as laparoscopy and robotic surgery are increasingly used, open pyeloplasty remains a valuable option in complex cases, particularly when anatomical landmarks are distorted or vascular anomalies are suspected.

The Anderson-Hynes dismembered pyeloplasty remains the gold standard, providing excellent functional outcomes and allowing anatomical correction tailored to individual variations.

Our case highlights the importance of preoperative imaging and individualized surgical planning in achieving optimal outcomes.

---

#### Compliance with ethical standards

##### *Disclosure of conflict of interest*

No conflict of interest to be disclosed.

##### *Statement of informed consent*

Informed consent was obtained from all individual participants included in the study.

---

#### References

- [1] Wein AJ, Kavoussi LR, Partin AW, Peters CA. Campbell-Walsh-Wein Urology. 12th ed. Elsevier; 2020.
- [2] Skolarikos A, Neisius A, Petřík A, et al. EAU Guidelines on Urolithiasis. European Association of Urology; 2023.
- [3] Türk C, Petřík A, Sarica K, et al. EAU Guidelines on Urolithiasis. European Urology. 2023.
- [4] Hidas G, Kastin A, Mullerad M, et al. Laparoscopic management of ureteropelvic junction obstruction in anomalous kidneys. Urology. 2008;72(2):257–261.
- [5] Sampaio FJ, Favorito LA. Ureteropelvic junction obstruction: anatomical and clinical aspects. International Braz J Urol. 2012;38(5):611–620.
- [6] Van den Hoek J, de Jong TP, Scheepe JR. Pelvic kidney and ureteropelvic junction obstruction: diagnostic and therapeutic challenges. Journal of Pediatric Urology. 2014;10(3):497–502.