

Lornoxicam induced Toxic Epidermal Necrolysis (TEN) in a 54 years old female: A case report and its systematic literature review with respect to its causes and treatment overview

Furqan Ul Haq ^{1,*}, Asad Riaz ², Nawab Ali ³, Syed Farooq Shafiq ⁴, Qazi Muhammad Farooq Wahab ⁵, Talha Moin Uddin ⁶, Jibran Ikram ⁷, Muhammad Ishaq Shah ⁸, Muhammad Hamza ⁹, Touseef Hamid ¹⁰, Muhammad Nouman ¹¹, Abid Ali ¹², Ijaz Hussain ¹³ and Aisha Maqbool ¹⁴

¹ Department of Radiation Oncology, Shifa International Hospital, Limited, Pakistan. ²

Department of General Surgery, Ayub Teaching Hospital, Abbottabad, Pakistan.

³ Department Anesthesia, Lady Reading Hospital Peshawar, Pakistan.

⁴ Department of General Medicine, Lady Reading Hospital Peshawar, Pakistan.

⁵ Department of General Medicine, Khyber Teaching Hospital Peshawar, Pakistan.

⁶ Department of Oncology, Shifa International Hospital, Islamabad, Pakistan.

⁷ Department of Internal Medicine, Rehman Teaching Hospital, Peshawar, Peshawar, Pakistan.

⁸ Department of Medicine, Hayatabad Medical Complex, Peshawar, Pakistan.

⁹ Internal Medicine, Advance International Hospital Islamabad, Pakistan.

¹⁰ Department of Medicine, Saidu General Teaching Hospital, Swat. Pakistan.

¹¹ Department of General Medicine, Khyber Teaching Hospital Peshawar, Pakistan.

¹² Department of Medicine, Saidu General Teaching Hospital, Swat. Pakistan.

¹³ Surgical ICU, Advance International Hospital Islamabad, Pakistan.

¹⁴ Department of Medicine, Niazi Medical College Sargodha Punjab Pakistan.

World Journal of Advanced Research and Reviews, 2024, 22(03), 1351–1361

Publication history: Received on 01 May 2024; revised on 16 June 2024; accepted on 19 June 2024

Article DOI: <https://doi.org/10.30574/wjarr.2024.22.3.1751>

Abstract

Background: Stevens–Johnson syndrome (SJS) and toxic epidermal necrolysis (TEN) are uncommon but life-threatening diseases mostly caused by drugs. Although various systemic immunomodulating agents have been used, their therapeutic efficacy has been inconsistent.

Introduction: Toxic epidermal necrolysis is a severe dermatological condition that can be life-threatening as it damages the mucosa and epidermis layers of the skin with widespread necrosis, erythema, and the formation of bullae on various mucosal surfaces of the genitourinary, gastrointestinal, respiratory tracts, ocular and surrounding areas can also be affected, potentially leading to sepsis and death and is often triggered by drugs such as Amoxicillin, medications used for respiratory tract infections, hereditary noncompliance to certain drugs, Sulpha drugs (e.g., allopurinol), anti-epileptic drugs (e.g., phenytoin, Lamotrigine, carbamazepine, phenobarbital), NSAIDs (e.g., ibuprofen, Piroxicam, Paracetamol, Mefenamic acid, Diclofenac sodium, Tolmetin, Oxybutazone), Quinolones (e.g., ciprofloxacin, Trovafloxacin).

Methodology: In this research article we have explained our case report, as well as we have described the systematic literature review of TEN, We did a literature search using electronic bibliographic databases and Journals : such as ELSEVIER ,British Medical Journals ,MEDLINE (Ovid SP and PubMed), EMBASE, The Cochrane Library (Cochrane Database of Systematic Reviews (CDSR), and Cochrane Central Register of Controlled Trials (CENTRAL), as well as annual meetings abstracts from inception till Oct 2021. The literature search has focused mainly on randomized clinical trials, meta-analysis, phase II/III, and retrospective studies.

* Corresponding author: Furqan Ul Haq

Objectives

- Explained the case report in view of NSAID in old people can cause SJS/TEN.
- To explain the treatment options of SJS/TEN.

Results and conclusions: Despite the rarity of her lornoxicam-induced TEN, this case highlights the urgent need to recognize and detect drug-induced skin reactions early. The patient's complex presentation, including thrombotic microangiopathy and suspected disseminated intravascular coagulation, required a multidisciplinary approach including nephrology, dermatology, and hematology. A comprehensive management plan that includes hemodialysis, corticosteroids, antibiotics, and symptomatic treatment highlights the importance of individualized treatment strategies in managing such complex clinical scenarios. Research shows that the basic mechanism behind JS/TEN Fas-Fas ligand mediated apoptosis but the recent research studies suggested that the reactive oxygen species (ROS) as the initiating factor for keratinocyte damage and that it precedes the activation of the aforementioned apoptotic systems. Treatment includes steroids, immunoglobulins, TNF alpha inhibitors (Infliximab, adalimumab, gulumumab and Etanercept), plasma paresis, immune suppressive therapies such as cyclosporine. In symptomatic management patients can have dialysis for renal failure.

Keywords: SJS; TEN; NSAIDS; lornoxicam; Dermatology emergencies; Immunosuppressive therapies

1. Introduction

Toxic epidermal necrolysis is a severe dermatological condition that can be life-threatening as it damages the mucosa and epidermis layers of the skin. This condition results in widespread necrosis, erythema, and the formation of bullae on various mucosal surfaces of the genitourinary, gastrointestinal, and respiratory tracts of the patient. Ocular and surrounding areas can also be affected, potentially leading to sepsis and death. Steven Johnson syndrome is quite similar to toxic epidermal necrolysis; eventually, SJS can progress to toxic epidermal necrolysis in severe cases. Toxic Epidermal Necrolysis (TEN) is a severe skin condition often associated with adverse drug reactions. It is characterized by extensive detachment of the epidermis and can be life threatening. It typically involves more than 30% of the body surface area, while SJS involves less than 10% and primarily an idiopathic condition, often triggered by drugs such as Amoxicillin, medications used for respiratory tract infections, hereditary noncompliance to certain drugs, Sulpha drugs (e.g., allopurinol), anti-epileptic drugs (e.g., phenytoin, Lamotrigine, carbamazepine, phenobarbital), NSAIDs (e.g., ibuprofen, Piroxicam, Paracetamol, Mefenamic acid, Diclofenac sodium, Tolmetin, Oxybutazone), Quinolones (e.g., ciprofloxacin, Trovafloxacin), Macrolides (e.g., azithromycin, Clathromycin, Erythromycin), and Allopurinol (Aloprim, Zyloprim) (1). Lornoxicam, a novel NSAID, has been evaluated for chronic oral toxicity and was found to cause drug-related toxicity such as mortality, reduced body weight gain, and clinico-pathological changes in rats. These changes included anemia from blood loss, renal damage, and gastrointestinal mucosal lesions, some of which were not fully reversible (2). The pathogenesis of drug-induced TEN may involve immune mechanisms, with CD8-positive T cells (suppressor/cytotoxic T cells) implicated as potential mediators of epidermal damage in the condition (3). Several types of TEN are A. Ten along with spots, B. Ten without any spots, C. Consist of the intermediate state of SJS and TENS. In conclusion, TEN is associated with the use of certain medications, including NSAIDs like celecoxib and potentially lornoxicam. The condition may involve immune system components such as CD8-positive T cells contributing to the epidermal damage observed in TEN. Treatment includes steroids, immunoglobulins, TNF alpha inhibitors (Infliximab, adalimumab and Etanercept), plasma paresis, immunosuppressive therapies such as cyclosporine have shown promising results. In symptomatic management patients can have dialysis for renal failure (4).

1.1. History of present complaint

A 63-year-old female patient with a 10-year history of hypertension presented with complaints of drowsiness and hyponatremia. The patient has been shifted to the medical step-down unit for further evaluation. Previously, the patient had a history of an acute allergic reaction resulting in Steven Johnson syndrome progressing to TEN. Three weeks ago, the patient developed a blistering rash in upper limbs and lower limbs shown in Figure 1 and Figure 2. The patient also had vomiting, abdominal pain, oral ulcers, and fever. Hypotonic saline was administered for heart disease via a left catheter, but it was discontinued. Peripheral smear showed schistocytes, 4-5 cells. The patient is also suspected to have disseminated intravascular coagulation and thrombotic microangiopathy. The baseline investigations have been explained in Table 1. The management plan included plasmapheresis, steroids, antibiotics, and symptomatic treatment. Nephrology will perform hemodialysis on alternate days and conduct a workup for hyponatremia as the patient had acute renal failure. Dermatology was taken on board and has prescribed moisturizer gel and administered IV hydrocortisone. Hematology will address the suspected coagulation issues and transfusion cryoprecipitate. The patient denies vomiting, loose stools, and fever. Past medical history includes hypertension, with no diabetes or asthma. There

is no family history of note. On examination, the patient has a GCS of 15/15, heart rate of 70 bpm, normal SP02 on room air, equal bilateral chest sounds, normal cardiovascular sounds, and full power in all limbs with decreased response on plantar reflex. Random blood sugar is 113 mg/dl.

On presentation the patient findings have been discussed below.

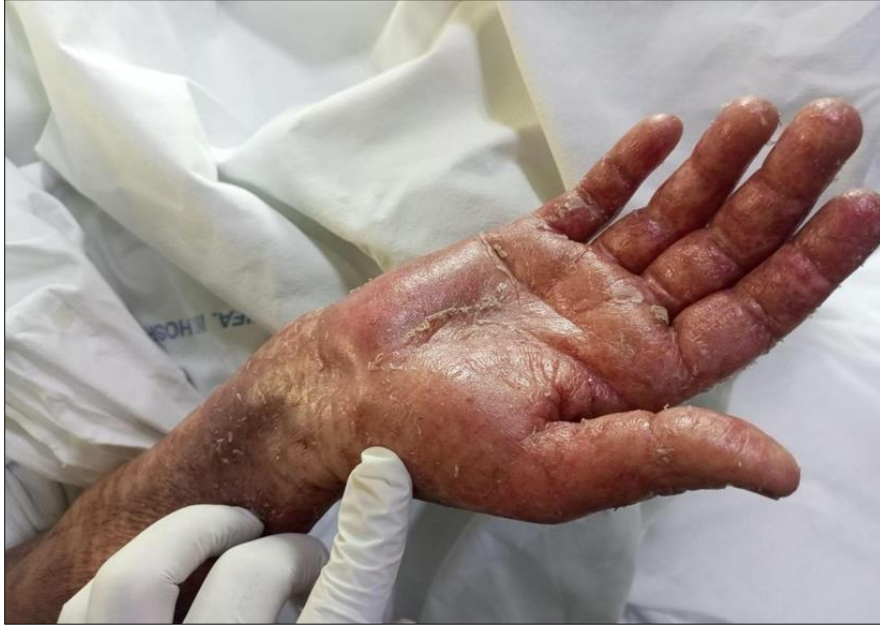

Figure 1 TEN hand showing Widespread Erythema and Rash, Ruptured bullae and Skin Detachment

1.1.1. Lower Limbs

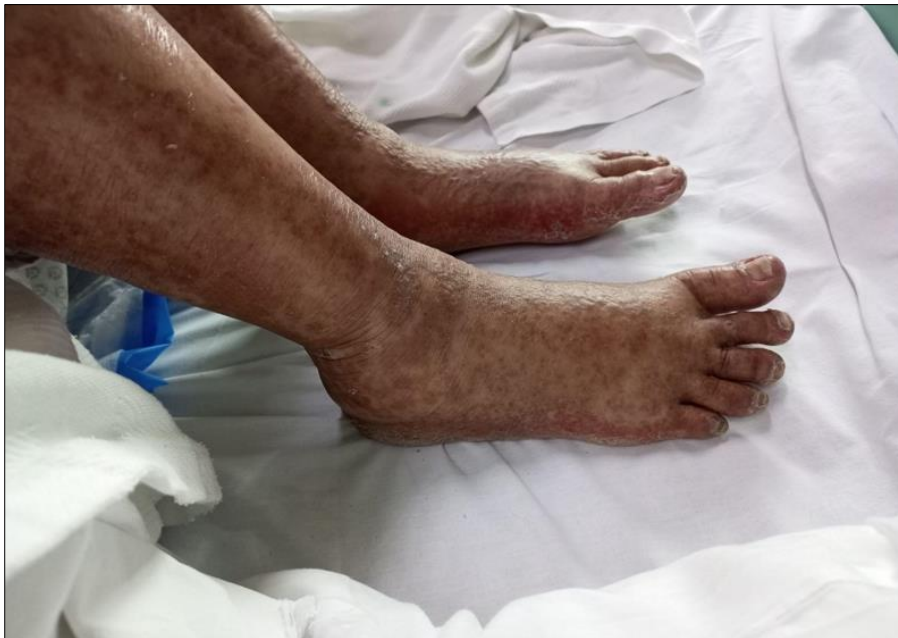

Figure 2 TEN Lower Limb showing Necrotic Epidermis (Dark discoloration)

1.2. Baseline investigations**Table 1** Baseline investigations of the patient on the time of admission:

WBC Total	29,860	(4000/UL -11000/UL)
RBC, Total	4.89	M(4.5 - 6.5)m/UL F(3.8 - 5.8)m/UL
Hemoglobin	10.6	M(13.0-18.0)g/dL F(11.6-16.5)g/dL
HCT	33.2	M(40 - 54)% F(38 - 47)%
MCV	67.9	(80 - 90)fL
MCH	21.7	(27 - 32)pg
MCHC	31.9	(33 - 38)g/dL
Platelet Count	351,000	(150,000-400,000)/UL
Neutrophils	97	(40 - 75)%
Lymphocytes	1	(20 - 45)%
Monocytes	1	(2 - 10)%
Eosinophils	1	(1 - 6)%
Basophil	0	(0 - 1)%
RDW	18.0	(11.5 - 13.6)%
Ionized Calcium	4.3	4.6 - 5.3 mg/dL
Chloride Serum	102	Adult 98 - 107 mEq/L Newborn 98 - 113 mEq/L
Bicarbonate Serum	17	Adult 22 - 29 mEq/L Newborn 13 - 22 mEq/L
Glucose Random	285	200 mg/dL
BUN	13	Children:5-18 mg/dL, Adult: 18-60 years 6-20 mg/dL 60-90 years 8-23 mg/dL
Urea Serum	27.82	Adult:16.6-48.5 mg/dL
CPKMB (CKMB)	0.6	Female upto 3.4 ng/mL, Male upto 7.2 ng/mL
CRP-High Sensitivity	117.72	upto 5.0 mg/L
Troponin-I High Sensitivity	28.5	Female Upto 15.6 pg/mL, Male Upto 34.2 pg/mL
pH	7.390	7.35 - 7.45
PCO2	29.5	32.0 - 48.0
PO2	38.2	83.0 - 108
(c)HCO3	17.5	22 - 29
Ca++	4.55	4.6 - 5.3 mg/dL
Base Excess	-6.5	-2 - +2
O2 Sat	64.5	94.0 - 98.0 %
Cl-	97.3	Newborn 98 - 113 mEq/L, Adult 98 - 107 mEq/L
K+	3.60	Newborn 3.7 - 5.9 mEq/L, Adult 3.5 - 5.1 mEq/L
Na+	135.1	Adult 136 - 145 mEq/L, Newborn 133 - 146 mEq/L
Blood Ketone (Beta-Hydroxybutyrate)	0.1	0.6 mmol/L

Abbreviations: WBCs: White blood cells; RBCs Red blood cells; HCT: hematocrit; MCV: Mean corpuscular volume; MCH: Mean corpuscular hemoglobin; MCHC: Mean corpuscular hemoglobin concentration; RDW: Red cell distribution width; GFR; Glomerular filtration rate; CKD-EPI: Chronic kidney disease epidemiology collaboration; AST: aspartate aminotransferase; ALT: Alanine transaminase; GGT: Gamma glutamyl transferase; M: Male; F: Female; g/dL: Gram per decilitre; fL: Femtoliter; pg: Picogram; dL: decilitre; U/L: Unite per liter; mg/dL: milligram per decilitre; ml/min/m²: milliliter per minute per meter square; S/Co: Signal to cut-off;

1.3. Radiologic investigations

1.3.1. X ray

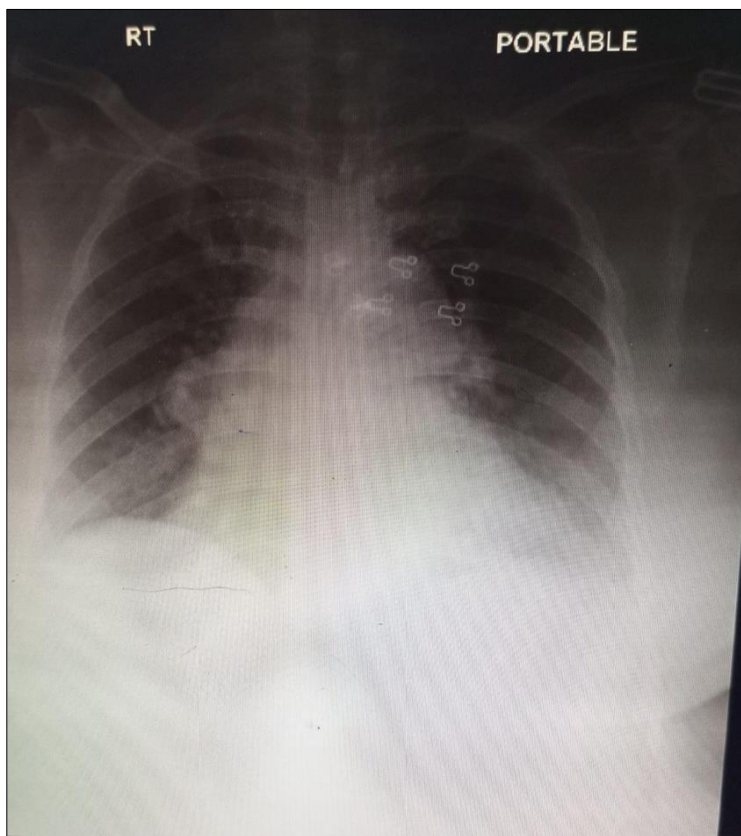


Figure 3 X ray showing Bilateral prominent bronchovascular markings are noted. Left CP angle is blunt, the right CP angle is shallow. Cardiomeastinal widening is likely accentuated by portable technique and AP projection. Visualized bony skeleton is unremarkable

Table 2 Antibodies profile done

Anti SM Antibody	Negative 0.1	<5 Negative 5-10 Equivocal >10 positive
Anti RNP Antinbody	Negative0.1	<5 Negative 5-10 Equivocal >10 positive
Anti Sm/RNP Antibody	Negative0.1	<5 Negative 5-10 Equivocal >10 positive
Anti SSA Ro 60 kD Antibody	Negative0.1	<5 Negative 5-10 Equivocal >10 positive

Anti SSb La Antibody	Negative0.1	<5 Negative 5-10 Equivocal >10 positive
Anti Jo-1 Antibody	Negative0.1	<5 Negative 5-10 Equivocal >10 positive
Anti Scl-70 Antibody	Negative0.1	<5 Negative 5-10 Equivocal >10 positive
Anti PM-Scl 100 Antibody	Negative0.1	<5 Negative 5-10 Equivocal >10 positive
Anti Ku Antibody	Negative0.1	<5 Negative 5-10 Equivocal >10 positive
Anti CENP A/B Antibody	Negative0.1	<5 Negative 5-10 Equivocal >10 positive
Anti PCNA Antibody	Negative0.1	<5 Negative 5-10 Equivocal >10 positive
Anti Mi-2 Antibody	Negative0.1	<5 Negative 5-10 Equivocal >10 positive

1.4. Treatment at Hospital

Table 3 Hospital based treatment received as an in patient

Serial No.	Drug Administered	Route	Dosage	Duration
1.	Paracetamol	Intravenous	1000	8 hourly as needed
2.	Omeprazole	intravenous	40mg	once daily
3.	Rocephin	intravenous	2 grams	once daily
4.	Heparin	subcutaneous	5000 Units	12 hourly
5.	Dexamethasone	Intravenous	60 mg	once a day
6.	Ondansetron	Intravenous	8 mg	8 hourly
7.	Motilium	Intravenous	10mg	12 hourly
8.	Normal Saline	Intravenous	80 ml/hour	continuously with BP monitoring

2. Literature review of presentations of different SJS

The epidemiology of TEN shows that the estimated incidence of TEN in the United States is 1.9 per million adults per year, while SJS affects around 9.3 per million people per year. Worldwide, there are numerous reports. In 1996, a German study estimated the yearly prevalence per million of both SJS and TEN cases to be around 1.9. The reported

figure for both SJS and TEN cases in the United Kingdom between 1995 and 2013 is as high as 5.76 cases per million inhabitants per year. While in Japan, TEN affects around one patient per million adults per year. There is a clear female sex predilection with a female to male ratio of 1.5 to 1. The majority of patients with TEN are between the 5th and 7th decade of life. However, it can affect any age group. In general, adult cases are mainly drug-induced, while infections are the main cause in children.

2.1. Pathophysiology

Previously considered to be Fas-Fas ligand mediated apoptosis but the recent research studies suggested that the reactive oxygen species (ROS) as the initiating factor for keratinocyte damage and that it precedes the activation of the aforementioned apoptotic systems. Oxidative stress is one of the proposed theories of TEN. Glutathione S-transferase-p (GST-p) is a biomarker of oxidative stress in keratinocytes. A higher level of this marker has been detected in TEN patients compared to other cutaneous drug reactions. The histopathology reveals that there is full-thickness epidermal necrosis with subsequent epidermal detachment.

The majority of patients present with some type of influenza-like symptoms (fever, malaise, arthralgia, rhinitis, and headache), which may last between up to 1 day to 3 weeks. Skin changes include cutaneous eruption ensues as an ill-defined dusky erythematous macular rash and bullae, which then coalesces to form sheet-like blisters. These blisters can easily slough, leaving a characteristic moist denuded dermis. They usually start in the face, presternal area before affecting the whole torso.

The mortality predictor score for TEN:

Table 4 Scortten Illness severity score

Serial no.	SCORTEN	Mortality risk
1	SCORTEN 0-1	> 3.2%
2	SCORTEN 2	> 12.1%
3	SCORTEN 3	> 35.3%
4	SCORTEN 4	> 58.3%
5	SCORTEN 5 or more	> 90%

TEN is a clinical diagnosis that is confirmed by early histological analysis of the affected skin. Early skin biopsy confirms the diagnosis and guides the treatment plan. A frozen section may be helpful to expedite the diagnosis.

SCORTEN is an illness severity score that has been developed to predict mortality in SJS and TEN cases. One point is scored for each of the seven criteria present at the time of admission which has been discussed in table 3.

The mainstay treatment of TEN is supportive care until re-epithelialization of the affected skin. Supportive measures include fluid resuscitation, pain management, wound care, and nutritional support. Fluid resuscitation using crystalloids should be guided by one of the standard burn resuscitation formulas (e.g., Parkland formula).

The treatment for TEN is observational and trials based, there is no evidence based effective therapy yet discovered including systemic steroid, plasmapheresis, cyclosporin, Anti-tumor necrosis factor-alpha (TNF-alpha), or intravenous immunoglobulin (IVIG).

Table 5 Different cases and researches with established source and treatment with outcomes

SERIAL NO	Presentation of patient	Drugs or any virus causing SJS	Treatment duration	Efficacy and side effects explained	Citation
1.	Generalized painful skin macular rash all over the body, tonsillitis with resolved pus, tongue affection (hyperemic and swollen) i.e., strawberry tongue, and encrusted lips. Nikolsky's sign was positive which indicated necrolysis.	Cephalosporin (Ceftriaxone)	Prednisolone (1.0 mg/kg/day)	-Started to improve from second day	Mkhoyan A, Hashmi MF, Khan F, Gyulazyan N, Asoyan V, Nersisyan V. Stevens-Johnson syndrome: a case report of possible cephalosporin-induced cutaneous adverse reaction. <i>J Infect Dev Ctries.</i> 2023 Oct 31;17(10):1493-1496. doi: 10.3855/jidc.18301. PMID: 37956371.
2.	Acute odynophagia, fevers, and diffuse body rash	Alpelisib	Methylprednisolone	Conditions started to improve.	Kurian CJ, Desai A, Rafferty W, Abou Hussein AK. Case report: Alpelisib-induced Stevens-Johnson syndrome. <i>Front Oncol.</i> 2022 Sep 28;12:954027.doi:10.3389/fo nc.2022.954027.PMID: 36249040;PMCID: PMC9554210.
3.	Cutaneous erythema around the face extending to the chest with ulceration of mucosal surfaces of the oropharynx	Daunorubicin	Stopping chemotherapy (Daunorubicin)	Conditions started to improve.	Shakya P, Sharma Nepal A. Daunorubicin induced Stevens-Johnson syndrome: A case report. <i>Clin Case Rep.</i> 2021 Jul 16;9(7):e04475. doi: 10.1002/ccr3.4475. PMID: 34295492; PMCID: PMC8283860.
4.	Fever and sore throat, as well as skin eruptions and oral mucosal and conjunctival ulcerations.	Carbamazepine	Intravenous (IV) hydrocortisone and IV antibiotics and stopping Carbamazepine	Condition did not improve with hydrocortisone Thus CsA of 5 mg/kg/day was started and improved condition	Al Rajaibi R, Al Rumhi T, Al Abri AM. Carbamazepine-Induced Stevens-Johnson Syndrome/Toxic Epidermal Necrolysis Overlap Treated Successfully with Oral Cyclosporine: Case report and literature review. <i>Sultan Qaboos Univ Med J.</i> 2021 Aug;21(3):491-494. doi: 10.18295/squmj.4.2021.002. Epub 2021 Aug 29. PMID: 34522420; PMCID: PMC8407905.
5.	Generalized erythematous rash over her body with facial puffiness, difficulty in swallowing, and mild discomfort while breathing	Dual antiepileptic drugs (Phenytoin and sodium valproate)	Antihistamines and corticosteroids (Inj. Hydrocortisone 100mg IV TDS).	Improved significantly within 15 days	Nakarmi P, Raut S, Manandhar S, Shrestha A. Dual Antiepileptics Induced Stevens-Johnson Syndrome: A Case Report. <i>JNMA J Nepal Med Assoc.</i> 2020 Oct 15;58(230):8-01-804. doi: 10.31729/jnma.5308. PMID:

					34504362; PMCID: PMC7654490.
6.	Fever with red, raised, pressure of fade rashes around the forehead. Multiple oral ulcers, mucosa congestion, and myrica rubra tongue	oseltamivir (60 mg, bid)	Intravenous immunoglobulin (IvIg), methylprednisolone 100 mg qd, tobramycin eye drops, recombinant bovine alkaline fibroblast growth factor and mupirocin ointment.	The patient's condition improved after 20 days.	Zuo W, Wen LP, Li J, Mei D, Fu Q, Zhang B. Oseltamivir induced Stevens-Johnson syndrome/toxic epidermal necrolysis-case report. <i>Medicine (Baltimore)</i> . 2019 May;98(19):e15553. doi: 10.1097/MD.0000000000001553. PMID: 31083216; PMCID: PMC6531182.

3. Discussion

Toxic epidermal necrolysis (TEN) is a severe immune-mediated side effect of the skin. It is characterized by detachment of the epidermis, which affects over 30% of the body surface. The mortality rate for TEN is over 20% and is usually attributed to infection and respiratory failure. (4)

Drug-induced toxic epidermal necrolysis (TEN) can and should cause her two “response patterns”: Stevens-Johnson syndrome and his TEN. The best results are processed in the write unit. (5)

In the past, TEN was thought to be a drug-induced immune response initiated by cytotoxic lymphocytes via the human leukocyte antigen (HLA)-restricted pathway. Several mediators contributing to cell death in TEN have been identified, including granulysin, soluble Fas ligand, perforin/granzyme, tumor necrosis factor alpha (TNF- α), and TNF-related apoptosis-inducing ligand. Granulysin is now considered the most important mediator of T cell proliferation (6)

Lornoxicam has a tolerability profile typical of an NSAID, with gastrointestinal disturbances being the most common adverse event. (7) Toxicity associated with lornoxicam in rats includes death, decreased weight gain, anemia, renal impairment, renal papillary necrosis, and gastrointestinal mucosal lesions. (8) Lornoxicam is generally well tolerated, although high doses (>16 mg) can cause gastrointestinal side effects similar to other NSAIDs (9)

The literature review of different case reports in table (1) highlights various cases of Stevens-Johnson syndrome induced by different drugs and their treatment strategies, providing valuable insights into the treatment of SJS and related complications.

- **Ceftriaxone and prednisolone:** The literature reports a case with generalized painful skin macular rash where prednisolone (1.0 mg/kg/day) was given, which resulted in improvement from the second day. This is consistent with the use of corticosteroids in the presented case, highlighting the efficacy of steroids in the management of SJS.
- **Alpelisib and methylprednisolone:** Another case involved acute odynophagia, fevers, and diffuse body rash, successfully managed with methylprednisolone. This supports the use of high-dose steroids in SJS, reflecting the current approach to treating the patient with IV hydrocortisone.
- **Daunorubicin and discontinuation of chemotherapy:** The case with skin erythema and mucosal ulceration improved after withdrawal of the problematic drug and shows the importance of identification and withdrawal of the causative agent in the treatment of SJS. While the specific perpetrator in this case is unclear, the principle of drug withdrawal is essential.
- **Carbamazepine and cyclosporine:** In a patient with SJS unresponsive to hydrocortisone, switching to cyclosporine led to improvement, indicating the potential need for alternative immunosuppressants when initial treatment fails. This suggests that cyclosporine may be considered as another treatment option if the patient's condition does not improve.

- **Dual antiepileptics and hydrocortisone:** A case involving phenytoin and sodium valproate induced SJS responded well to hydrocortisone, reinforcing the role of corticosteroids. Significant improvement within 15 days indicates the potential for a relatively rapid response to appropriate therapy, which is promising for the patient's current prognosis.
- **Oseltamivir and IVIG:** The use of intravenous immunoglobulin (IVIG) along with methylprednisolone in oseltamivir-induced SJS has shown improvement within 20 days. This combination therapy could be considered in the current patient if the response to steroids alone is inadequate.

Following all the literature is the essential role of corticosteroids in the management of SJS, which is consistent with the case report treatment approach. However, variability in response suggests that adjunctive therapies such as IVIG or cyclosporine may be necessary depending on patient progression. Additionally, the importance of early identification and arrest of the offender is a critical aspect of management that requires constant consideration in this case.

4. Conclusion

Despite the rarity of her lornoxicam-induced TEN, this case highlights the urgent need to recognize and detect drug-induced skin reactions early. The patient's complex presentation, including thrombotic microangiopathy and suspected disseminated intravascular coagulation, required a multidisciplinary approach including nephrology, dermatology, and hematology.

The systematic review of different studies shows that a comprehensive management plan that includes hemodialysis, corticosteroids, antibiotics, and symptomatic treatment highlights the importance of individualized treatment strategies in managing such complex clinical scenarios. Considering the potential severity of TEN and the important role of early intervention, this case provides valuable insight into the range of side effects associated with lornoxicam. It also highlights the need for caution when prescribing nonsteroidal anti-inflammatory drugs (NSAIDs) to patients with a history of severe allergic reactions. Further research is needed to elucidate the mechanisms underlying lornoxicam-induced TEN and develop prevention and treatment guidelines for high-risk patients.

Compliance with ethical standards

Disclosure of conflict of interest

No conflict of interest to be disclosed.

References

- [1] Mockenhaupt, M.; Viboud, C.; Dunant, A.; Naldi, L.; Halevy, S.; Bouwes Bavinck, J.N.; Sidoroff, A.; Schneck, J.; Roujeau, J.C.; Flahault, A. Stevens-Johnson syndrome and toxic epidermal necrolysis: Assessment of medication risks with emphasis on recently marketed drugs. The EuroSCAR-study. *J. Investig. Dermatol.* 2008, 128, 35–44.
- [2] Berger, P., Dwyer, D., & Corallo, C. (2002). Toxic Epidermal Necrolysis After Celecoxib Therapy. *Pharmacotherapy: The Journal of Human Pharmacology and Drug Therapy*, 22. <https://doi.org/10.1592/phco.22.13.1193.33513>.
- [3] Miyauchi, H., Hosokawa, H., Akaeda, T., Iba, H., & Asada, Y. (1991). T-cell subsets in drug-induced toxic epidermal necrolysis. Possible pathogenic mechanism induced by CD8-positive T cells. *Archives of dermatology*, 127 6, 851-5. <https://doi.org/10.1001/ARCHDERM.1991.01680050095011>.
- [4] TH REFERENCE OF INTRO Chang HC, Wang TJ, Lin MH, Chen TJ. A Review of the Systemic Treatment of Stevens-Johnson Syndrome and Toxic Epidermal Necrolysis. *Biomedicines*. 2022 Aug 28;10(9):2105. doi: 10.3390/biomedicines10092105. PMID: 36140207; PMCID: PMC9495335.
- [5] Singh N, Phillips M. Toxic Epidermal Necrolysis: A Review of Past and Present Therapeutic Approaches. *Skin Therapy Lett*. 2022 Sep;27(5):7-13. PMID: 36469487.
- [6] Chan, H. (1984). Observations on drug-induced toxic epidermal necrolysis in Singapore. *Journal of the American Academy of Dermatology*, 10 6, 973-8. [https://doi.org/10.1016/S0190-9622\(84\)80317-5](https://doi.org/10.1016/S0190-9622(84)80317-5).
- [7] Harris, V., Jackson, C., & Cooper, A. (2016). Review of Toxic Epidermal Necrolysis. *International Journal of Molecular Sciences*, 17. <https://doi.org/10.3390/ijms17122135>.

- [8] Balfour, J., Fitton, A., & Barradell, L. (1996). Lornoxicam. A review of its pharmacology and therapeutic potential in the management of painful and inflammatory conditions.. *Drugs*, 51 4, 639-57 . <https://doi.org/10.2165/00003495-199651040-00008>.
- [9] Pohlmeier-Esch, G., Mehdi, N., Clarke, D., & Radhofer-Welte, S. (1997). Evaluation of chronic oral toxicity and carcinogenic potential of lornoxicam in rats.. *Food and chemical toxicology : an international journal published for the British Industrial Biological Research Association*, 35 9, 909-22 . [https://doi.org/10.1016/S0278-6915\(97\)00062-8](https://doi.org/10.1016/S0278-6915(97)00062-8).
- [10] Berry, H., Bird, H., Black, C., Blake, D., Freeman, A., Golding, D., Hamilton, E., Jayson, M., Kidd, B., & Kohn, H. (1992). A double blind, multicentre, placebo controlled trial of lornoxicam in patients with osteoarthritis of the hip and knee.. *Annals of Rheumatic Diseases*, 51, 238 - 242. <https://doi.org/10.1136/ard.51.2.238>.