

A case report of intrapulmonary mature teratoma with aspergilloma

Gohar Ali ¹, Muhammad Kashif Dawar ¹, Almas ¹, Imran Tahir ², Ahmad Reshad Payenda ³ and Wasim Khan ^{4,*}

¹ General Surgery Department, Hayatabad Medical Complex Peshawar, Pakistan.

² Thoracic Surgery Department, Hayatabad Medical Complex Peshawar, Pakistan.

³ Neurosurgery Department, Northwest General Hospital and Research Centre Peshawar, Pakistan.

⁴ Department of Orthopedic Surgery, Northwest General Hospital and Research Centre Peshawar, Pakistan.

World Journal of Advanced Research and Reviews, 2024, 24(01), 1543–1547

Publication history: Received on 05 September 2024; revised on 15 October 2024; accepted on 17 October 2024

Article DOI: <https://doi.org/10.30574/wjarr.2024.24.1.3151>

Abstract

Introduction: Teratomas are benign germ cell tumors composed of components from the ectoderm, mesoderm, and endoderm. While germ cell tumors account for 10-20% of anterior mediastinal masses, intrapulmonary teratomas (IPTs) are extremely rare. They typically occur in the third decade of life and may present as metastasis from gonadal tumors. This study reports a rare case of a mature IPT in the right middle lobe of the lung, initially misdiagnosed as pulmonary tuberculosis and aspergilloma.

Case Presentation: A 17-year-old female presented with a 4-year history of cough with sputum and two episodes of hemoptysis. Despite negative tuberculosis tests, she was treated with anti-tubercular drugs and multiple antibiotics. Imaging revealed a 5.5-cm cavitory mass in the right middle lobe containing an aspergilloma. Surgical resection was performed, and the pathology confirmed a mature teratoma with aspergilloma colonization. The patient recovered well postoperatively and showed no signs of recurrence.

Discussion: Teratomas are germ cell tumors rarely found in the lungs, with fewer than 100 cases reported globally. Diagnosis is challenging due to overlapping symptoms with other conditions such as tuberculosis. In this case, the presence of an aspergilloma further complicated the diagnosis. Complete surgical resection led to the patient's recovery.

Conclusion: Mature IPTs with aspergilloma are extremely rare, and should be considered in the differential diagnosis of cavitory lung lesions. Early diagnosis and surgical resection are crucial for successful treatment.

Keywords: Intrapulmonary Teratoma; Aspergilloma; Germ Cell Tumor; Mature Teratoma; Hemoptysis.

1. Introduction

Teratomas are benign tumors, consisting of components of three germinal layers (ectoderm, mesoderm, and endoderm). In adults, germ cell tumors (GCT) make up 10–20% of all anterior mediastinal masses [1]. Intrapulmonary Teratomas (IPTs) are rare. They can occur at any age but are mostly seen in the third decade of life, with equal predilection for both [2,3]. In the lung, teratoma may present as metastasis from Gonadal GCT such as Seminoma, Embryonal Cell Carcinoma, Yolk sac cancers, and Choriocarcinoma [1].

The Objective of this study is to report a rare case of mature IPTs in the middle lobe of the right lung and anterior mediastinum, presenting as a cavitating intraparenchymal lesion, containing fungal-ball previously treated as an aspergilloma lung secondary to suspected pulmonary tuberculosis to help spread the diagnosis and treatment of this rare condition.

* Corresponding author: Wasim Khan

2. Case presentation

A 17-year-old female patient presented with a cough with sputum for 4 years and two episodes of hemoptysis in the last 6 months. For a few months, the cough was accompanied by a fever, but the fever then subsided. Coughing occurred more than ten times, more frequently in the morning than in the evening associated with yellowish color sputum about 2mL in volume. She had two episodes of hemoptysis in the last 6 months. It was about 5 ml each time.

She had a past history of anti-tubercular medication taken 4 years ago for the same symptoms, even though the workup for TB was negative. She had been using multiple antibiotics and antiallergic medications during these symptomatic periods and had consulted the pulmonologists. She had no other past medical or surgical history. She was a non-smoker and non-addicted.

On primary survey, his airway was patent; his respiratory rate was 20 breaths per minute with an oxygen saturation of 98% on room air. Decreased breath sounds as well as bronchial sounds were auscultated in the right lower thorax. The heart rate was 76 beats per minute with a blood pressure of 130/84 mm Hg. Clinically, the patient appeared calm and hemodynamically stable.

On workup, a chest X-ray (Figure 1) showed heterogeneous opacity in the right middle zone with an air crescent sign, pathognomonic of aspergilloma lung. A 5.5-cm mass in the right middle lobe with cavitation and an intracavitary mass adherent to the pericardium were discovered on the chest Computed Tomography scan (CT Scan). (Figure 2).

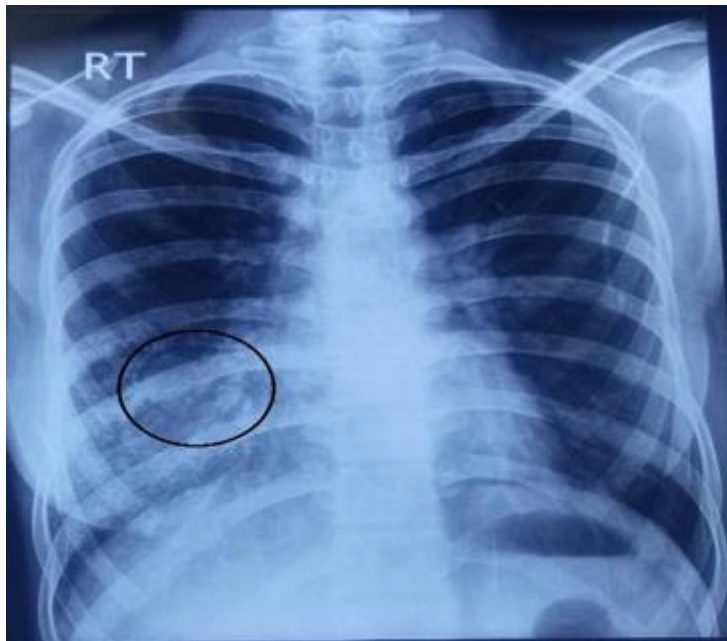

Figure 1 Chest X-Ray showing right lower lung opacity with an air crescent sign (encircled in black)

After optimization for surgery and anesthesia, she underwent surgery. The thoracic cavity was entered via a right posterolateral thoracotomy, and there were hard swellings arising from the anterior mediastinum adherent with the pericardium communicating with the middle lobe of the lung and a cavity in the center of the mass. Inside the cavity was an aspergilloma. The mass was adherent to the pericardium and phrenic nerve, which were separated with difficulty. The cavity was evacuated of aspergilloma, the mass was dissected, and wedge resection of the middle lobe was done. Removal of the adhesions of pericardium and phrenic nerve with mass was successfully done, and the cavity was washed and then closed with Prolene suture. The remaining portion of the lung was also closed. The chest was closed after leaving the chest tube. The patient was successfully recovered from anesthesia and shifted to a high-dependency unit. The patient was discharged home on the 4th postoperative day with normal vitals and no post op complications.

The resected specimen was sent for histopathologic examination. Gross specimens showed multiple tan, gray, and white tissue pieces collectively measuring 50 x 40 x 0 mm. Serial slicing revealed tan, gray, and white fibrofatty tissue, hair shafts, and a cystic cut surface (filled with white-clear fluid). Microscopic examination revealed well-differentiated cells

showing squamous epithelium, hair follicles, sebaceous glands, pancreatic tissue, colonic tissue, and cartilage tissue. No immature components were seen in sections. These findings were suggestive of mature teratoma.

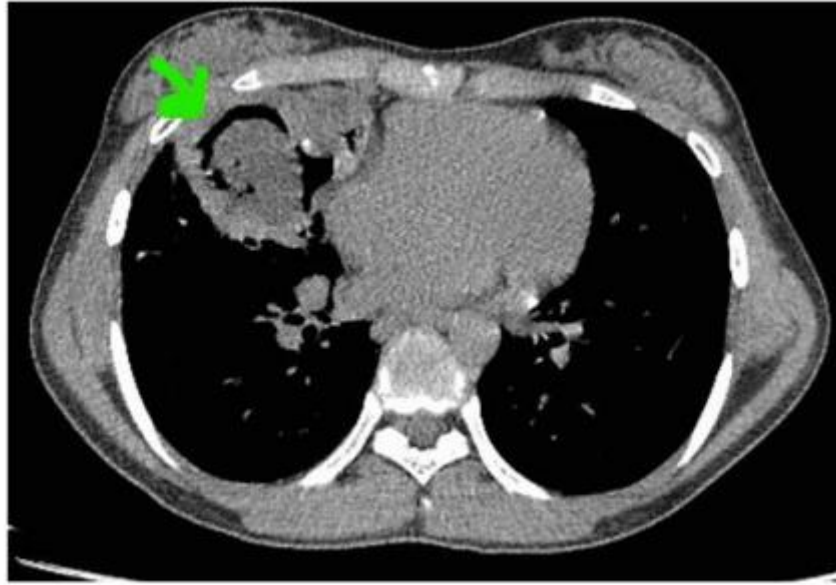


Figure 2 CT scan revealing a thick-walled cavity in the right middle lobe with an air crescent sign (green arrow) and an intracavitary lesion.

The patient was re-evaluated as an outpatient two weeks after surgery. She had no shortness of breath, no cough, no fever, and no other complaints. On physical examination, the chest was resonant and clear to auscultation. She had a smooth postoperative course up to that point and was scheduled for follow-up one month later. The chest x-ray showed good bilateral lung expansion with no evidence of a residual lesion or recurrence.

3. Discussion

Teratomas are germ-cell tumors arising from pluripotent embryonic cells. These are most commonly present in sex organs and rarely involve other organs. A very small percentage of such extra-gonadal tumors found in the mediastinum account for less than 2% of all the cases described [4]. These are rare in the lungs and mediastinum, and they are most likely benign, 80% mature, and slow-growing in nature [2]. Less than 100 cases have been reported in the world's literature until 2022. They commonly involve the upper lobes of the lungs [2]. In our case, it involved the middle lobe and anterior mediastinum. They are believed to arise from the third pharyngeal pouch. Derivatives from any of the three germinal layers can be found within the tumor, mostly including hair, bone, and teeth. Other tissues include respiratory epithelium, pancreatic cartilages, tissues, cartilages, and muscles [4]. A CT scan is the modality that can differentiate our case from masses in the anterior mediastinum; the findings on it were combinations of fat, fluid, calcifications, and cavitating masses, highly specific for teratoma. And is helpful in distinguishing it from other common anterior mediastinal tumors, such as thymomas [5-7]. Most of the patients with pulmonary teratoma present clinically with variable manifestations like chest pain (52%), blood in the sputum (42%), a productive cough (39%), and hair expectoration (13%). Other symptoms include bronchiectasis, post-obstructive pneumonia (16%) and few with pyothorax [4].

Hemoptysis is due to erosion of bronchus by teratoma that is life threatening [8]. The patient had a long history of productive cough and radiologically significant middle lobe cavitory opacity on x-ray chest; she was treated as if she had pulmonary tuberculosis and was given ATT (anti-tubercular treatment). Her tuberculous workup was negative. Hemoptysis is a late symptom in this case, indicating the slow growth of a mass in the mediastinum that has not caused any erosion in the previous four years. However, in the last six months, she had observed two episodes of blood in sputum in the morning of the same day. As a result, the mass was probably eroding its surroundings. The adhesions of the mass with the surrounding pericardium and right phrenic nerve were released with difficulty. Other cavitory lung diseases like TB are sarcoidosis, tumors, pulmonary fibrosis, bronchiectasis and histoplasmosis [9].

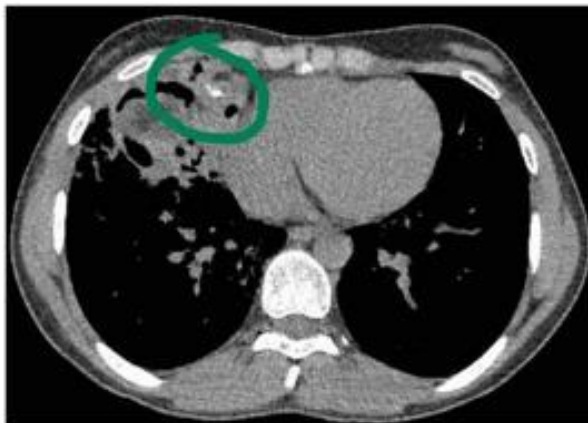


Figure 3 CT scan showing calcifications opacity and variant densities of tissues

Teratomas are either benign and well differentiated, known as mature teratomas, or malignant and poorly differentiated, known as immature teratomas. Benign tumors are common, and most of them are encapsulated and do not have the potential to spread distantly. Therefore, surgical resection can completely cure [4].

Aspergilloma in mature teratoma is very unusual but occurs in those patients with cavitory lesions, and no such cases have been reported in Pakistan [4]. The growth of aspergilloma in lung cavities is due to the affinity of *Aspergillus* species, which are ubiquitous aerophilic fungi that have a relationship with teratoma forming cavities [10]. The histological specimen is suggestive of aspergilloma with mature teratoma in the lung. Surgical resection of the tumor cured the patient's symptoms completely, and she was improved after two weeks of follow-up.

4. Conclusion

Aspergilloma with mature teratoma in the lungs is a rare condition. The diagnosis of such a condition is challenging to clinicians and radiologists, so this condition should be included in the differential diagnosis of any patient with hemoptysis and a negative tuberculosis workup having cavitory lesions in the lungs with soft tissue masses or opacity on CT Scan or Chest X-Ray respectively. Particularly, the enhanced attenuation CT finding is a hint at the possible presence of *Aspergillus* fungus colonizing the teratoma. Surgical excision was the only treatment of choice and improved the symptoms within a few weeks.

Compliance with ethical standards

Acknowledgments

Dr Ikram Ullah Khan (Department of Botany, Abdul Wali Khan University Mardan Pakistan, ikramullah@awkum.edu.pk), helped us in reviewing the article and guided us throughout the process for which we acknowledge and appreciate his efforts and help.

Disclosure of conflict of interest

No conflict of interest to be disclosed.

Statement of informed consent

Informed consent was obtained from all individual participants included in the study.

References

- [1] Nuti R, Bodhireddy S, Thirumala S. Mixed germ cell tumor of mediastinum/lung masquerading as hemangioma in fine needle biopsy. *Indian J Pathol Microbiol.* 2013;56(2):158–60.

- [2] Mardani P, Naseri R, Amirian A, Shahriarirad R, Anbardar MH, Fouladi D, et al. Intrapulmonary mature cystic teratoma of the lung: case report of a rare entity. *BMC Surg.* 2020 Sep 14;20(1):203.
- [3] Bawazir AA, Alrossais NM, BinSaleh Y, Alamodi AA, Alshammari A. A case report of intrapulmonary teratoma in the right upper lung zone in a 35-year-old female patient. *Cureus.* 2019 Jan;11(1).
- [4] Ahmed S, Kibzai H, Shahzad T, Hasnain Fatimi S, Bilal Qureshi M. Cough, Hemoptysis And Hair Expectoration: An Intrapulmonary Teratoma. *J Coll Physicians Surg Pak.* 2018 Mar 16;28(3):243–4.
- [5] Pikin O, Kolbanov K, Kazakevich V, Korolev A. Mediastinal mature cystic teratoma perforating into the lung. *Interact Cardiovasc Thorac Surg.* 2010 Dec;11(6):827–9.
- [6] Yazgan S, Gürsoy S, Türk F, Dinç ZA. Conjunction of a Fungus Ball and a Pulmonary Tumourlet in a Bronchiectatic Cavity. *The Korean Journal of Thoracic and Cardiovascular Surgery.* 2018 Apr;51(2):138.
- [7] Omachi N, Kawaguchi T, Shimizu S, Okuma T, Kitaichi M, Atagi S, Yoon HE, Matsumura A. Life-threatening and rapidly growing teratoma in the anterior mediastinum. *Internal Medicine.* 2015;54(19):2487-9.
- [8] Thapaliya P, Fatima T., Abid A, Mazcuri M, Sikander N, Ahmad T, et al. Aspergilloma or intrapulmonary teratoma - time to rethink. *Int Surg J.* 2020 Nov 27;7(12):4169–71.
- [9] Kobayashi T, Yamamoto H, Ohtsuka T, Imura Y. [Resection of a mediastinal teratoma that perforated the lung and combined with aspergilloma in the tumor cyst]. *Zasshi J Nihon Kyobu Geka Gakkai.* 1992 Nov;40(11):2091–4.
- [10] Bezabih A, Atnafu A. Mature teratoma with aspergilloma. *East Cent Afr J Surg.* 2019 Jan 1;23(3):119–22..