

## Immune thrombocytopenic purpura in children: An update

Bennani Kenza <sup>1,2,\*</sup>, Tlamçani Imane <sup>1,2</sup> and Amrani Hassani Moncef <sup>1,2</sup>

<sup>1</sup> Department of Hematology, Central Laboratory of Medical Biological Analyses, Hassan II University Hospital, Fez, Morocco.

<sup>2</sup> Faculty of Medicine, Pharmacy, and Dental Medicine of Fez, Sidi Mohamed Ben Abdellah University, Fez, Morocco.

World Journal of Advanced Research and Reviews, 2024, 23(02), 1456–1461

Publication history: Received on 09 July 2024; revised on 15 August 2024; accepted on 17 August 2024

Article DOI: <https://doi.org/10.30574/wjarr.2024.23.2.2485>

### Abstract

Immune thrombocytopenic purpura, also known as Werlhof's disease, is the most common cause of thrombocytopenia in children. While the majority of childhood Immune thrombocytopenic purpura cases are benign and resolve spontaneously, a rigorous evaluation of bleeding potential using the Buchanan score remains essential. Indeed, in rare situations, the disease can progress to severe forms threatening life prognosis. The diagnosis of immune thrombocytopenic purpura relies on a combination of clinical, biological criteria, and exclusion of other causes of thrombocytopenia. Management of Immune thrombocytopenic purpura varies based on its form, severity of bleeding, and impact on the child's quality of life. For mild cases, watchful waiting may be sufficient. However, for severe forms or those with high bleeding risk, specific treatments are considered. These include intravenous immunoglobulins, corticosteroid therapy, splenectomy, immunosuppressants, and thrombopoietin analogs. In recent years, significant progress has been made in the genetics of constitutional thrombocytopenia, allowing a revision of chronic Immune thrombocytopenic purpura diagnoses by identifying inherited genetic abnormalities. The growing understanding of Immune thrombocytopenic purpura mechanisms, combined with genetic and therapeutic advances, offers promising prospects for optimizing disease management and improving the quality of life of affected children.

**Keywords:** Purpura; Immune thrombocytopenia; Child; Update

### 1. Introduction

Immune thrombocytopenic purpura (ITP) is an acquired autoimmune disease characterized by a low and isolated count of circulating platelets below 100,000/mm<sup>3</sup> [1]. ITP can be classified into two subtypes: primary ITP, where no specific cause is identified and diagnosed by exclusion, and secondary ITP, associated with an underlying condition such as viral infections (Human immunodeficiency virus "HIV", hepatitis C, Epstein-Barr virus "EBV"), underlying autoimmune diseases, hematologic disorders, or malignancies [2, 3]. The aim of this review is to provide an updated overview of the literature on this condition.

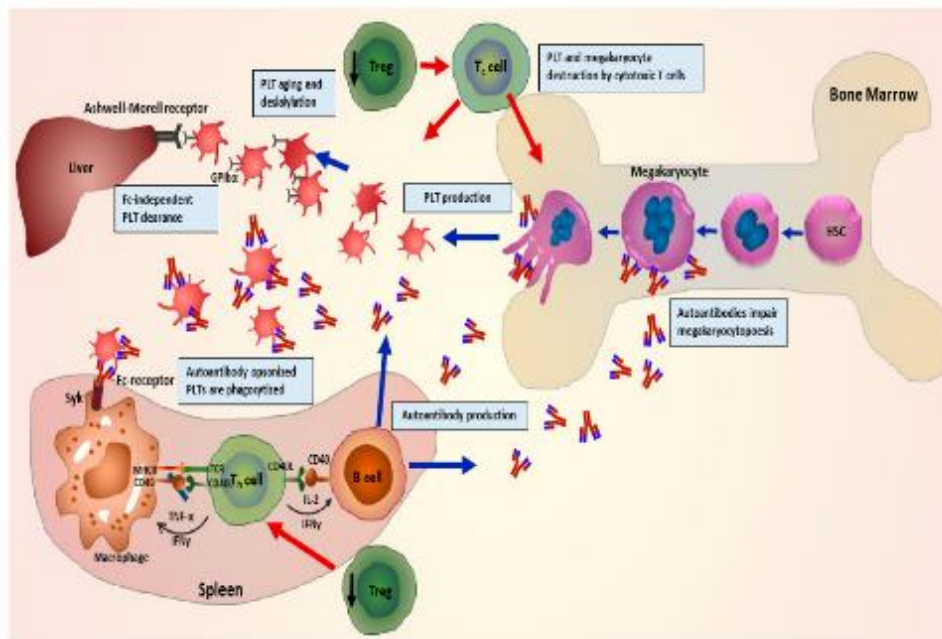
### 2. Epidemiology

ITP is the primary cause of peripheral thrombocytopenic purpura in otherwise healthy children, with an annual incidence of 5 per 100,000 children [4, 5]. It is more common in young children, peaking between 1 and 5 years of age, and shows a male predominance [5,6]. A seasonal increase in winter is observed, attributed to viral infections [5]. Currently, there is no national registry to assess the prevalence of ITP in Morocco.

\* Corresponding author: Bennani Kenza

### 3. Pathophysiology

The pathophysiology of ITP remains complex and incompletely understood, involving an intricate interplay between humoral and cellular immune mechanisms, as well as genetic and environmental factors (Fig. 1).



**Figure 1** Pathophysiology of ITP [7].

ITP is a disease characterized by autoimmune thrombocytopenia, where platelets are prematurely destroyed in the spleen, liver, or both, primarily through mechanisms involving autoantibodies directed against platelet surface glycoproteins such as GPIIb/IIIa, GPIb-IX, and GpIaIIa. These opsonized antibodies promote phagocytosis of platelets by splenic macrophages via their Fc $\gamma$  receptors and can induce immune complex formation and complement activation, thereby contributing to platelet lysis [8].

Although anti-platelet antibodies are observed in approximately 60% of patients, nearly half do not have such antibodies, suggesting the involvement of alternative mechanisms such as T cell abnormalities. Studies indicate a skewing of helper T cells (Th) toward types 1 (Th1) and 17 (Th17), along with a decrease in regulatory T cells, which may promote an exaggerated immune response directed against platelets. Additionally, CD8 $^{+}$  T lymphocytes have been identified to play a role in direct cytotoxicity against platelets and megakaryocytes [7,8].

In addition to peripheral platelet destruction, there is also a defect in marrow production, likely due to an autoimmune response against megakaryocytes. This phenomenon is influenced by abnormalities in thrombopoietin (TPO) regulation, essential for platelet production, although TPO levels are not increased in ITP [9].

Genetic predisposition is involved in ITP, implicating Human Leukocyte Antigen (HLA) systems, MHC class I polypeptide-related sequence A (MICA), Human Platelet Antigen (HPA) systems, genes encoding Fc fragments of immunoglobulins, and various cytokines [10].

Lastly, environmental factors appear to contribute to ITP predisposition. Associations between ITP and various viral infections, including HIV, hepatitis C, cytomegalovirus, and EBV, have been observed, and seasonal environmental factors can trigger or exacerbate the disease, with a winter predominance associated with viral infections [11, 12].

## 4. ITP in children: diagnostic approach

### 4.1. Evocative signs

ITP should be suspected in cases of abrupt onset of isolated hemorrhagic syndrome, varying in severity and location, characterized mainly by skin manifestations such as petechial and/or ecchymotic purpura, and sometimes subcutaneous hematomas, as well as mucosal or visceral bleeding [4]. Major hemorrhages are defined by the International Childhood ITP Registry (ICIS) as intracranial bleeding or other evident internal or mucosal bleeding resulting in anemia or requiring local treatment to stop the bleeding. Such hemorrhages remain rare in immune thrombocytopenic purpura [6]. Clinical examination is typically unremarkable except for hemorrhagic signs and the potential impact of the hemorrhagic syndrome in an otherwise healthy child [4].

### 4.2. Factors of severity

The assessment of bleeding risk is crucial during clinical examination as it guides therapeutic management. Typically, it begins with the use of the Buchanan score, which classifies the bleeding syndrome from 0 to 5 based on severity and extent of lesions [4] (Table 1). This bleeding score is commonly used to assess the severity of ITP and indicates that most children do not experience severe bleeding despite low platelet counts. It also emphasizes that the severity of cutaneous and mucosal bleeding does not predict the risk of potentially fatal bleeding, including intracranial hemorrhages. In children, clinical features and symptoms associated with ITP significantly influence therapeutic decisions.

**Table 1** Revised Buchanan bleeding score in children with ITP

| Grade   | Severity                | Description  |
|---------|-------------------------|--|
| Grade 0 | None                    | No clinical signs of bleeding  |
| Grade 1 | Minor                   | Few petechiae (<100) and/or 5 small bruises (<3 cm)  |
| Grade 2 | little severe           | Multiple petechiae (>100) and/or > 5 large bruises (>3 cm in diameter)                                 |
| Grade 3 | Moderate                | Mucosal bleeding: epistaxis, intraoral blisters, hematuria, metrorrhagia...                            |
| Grade 4 | Severe                  | Mucosal bleeding leading to a decrease in hemoglobin levels of 2g/dl or suspicion of internal bleeding |
| Grade 5 | vital prognosis at risk | Bleeding documented in the central nervous system or fatal bleeding from any site                      |

### 4.3. Biological analyses

Complete blood count (CBC) and peripheral blood smear are essential for diagnosis. They help identify isolated thrombocytopenia without abnormalities in other blood cell lineages or the presence of abnormal cells or platelet size anomalies [4]. CBC is performed on citrated tubes to rule out pseudo-thrombocytopenia due to platelet clumping with EDTA. In approximately 80% of cases, the platelet count at initial presentation is below  $20 \times 10^9 /L$  in children with ITP. A microcytic hypochromic anemia may be observed, but it should be proportional to the extent and duration of the bleeding syndrome [4]. Bone marrow examination is not recommended for children with recently diagnosed typical ITP. However, bone marrow examination should be considered mandatory in children newly diagnosed with ITP presenting with atypical signs, such as:

- Bone pain or a tumoral syndrome on clinical examination.
- Abnormalities in other blood cell lineages on CBC or presence of atypical cells on peripheral blood smear.
- Failure of initial treatment.

These patients should be referred to a specialized pediatric hematology center for evaluation and management [13]. Additional laboratory tests recommended at diagnosis and before any treatment include a Coombs test to screen for autoimmune hemolytic anemia and measurement of immunoglobulin levels (IgA, IgG, and IgM) to rule out immune deficiency [4].

#### 4.4. Differential diagnosis

- Hereditary thrombocytopenia: The diagnosis will be guided by the existence of a similar family history, the onset of symptoms very early in life and, biologically, an abnormal mean platelet volume and possibly failure of the first line of treatment. A genetic study is recommended if the panel is available [14].
- Other autoimmune diseases that may be associated with thrombocytopenia include systemic lupus erythematosus (SLE), common variable immunodeficiency (CVID) and autoimmune lymphoproliferative syndrome (ALPS). Their diagnosis is difficult and should be made in the presence of multiple autoimmune cytopenias [14].
- HIV infection in patients at risk.

---

#### 5. Evolution

The course of ITP is variable and unpredictable, ranging from an acute form that resolves spontaneously to a chronic form requiring long-term treatment. There are generally three phases: acute ITP, characterised by a duration of no more than 3 months after diagnosis; persistent ITP, with a duration of 3 to 12 months after diagnosis, encompassing patients who have not experienced spontaneous remission or maintained a complete response after treatment; and finally chronic ITP, defined by a duration of more than 12 months [4]. Progression to chronicity is multifactorial. One hypothesis suggests a genetic predisposition to progression to chronicity in patients with a CNR1 deletion, as described in the literature [4,5].

The course of ITP after treatment is classified according to the following criteria: A response to treatment is defined by at least a doubling of the baseline platelet count with a total platelet count greater than  $30,000/\text{mm}^3$ . A complete response is characterised by a platelet count  $\geq 100,000/\text{mm}^3$ ; a partial response corresponds to a doubling of the platelet count which remains between 30,000 and  $100,000/\text{mm}^3$ . Refractory ITP is defined as ITP that does not respond to splenectomy or relapses after splenectomy and requires additional treatment [15, 16]

---

#### 6. Prognosis

The prognosis is favorable for acute ITP as most patients recover spontaneously. Patients with chronic ITP almost always require treatment, and relapses are common. A complete response to first-line treatment can occur in approximately 20% of patients, with around 60% achieving a partial response [17]

---

#### 7. Therapeutic indications

##### 7.1. Withhold treatment with clinical and biological monitoring

Patients with asymptomatic moderate thrombocytopenia (platelets  $> 30 \text{ g/L}$ ) with ITP usually do not require treatment. However, it may be useful to propose a short course of corticosteroids at the time of diagnosis, even if the thrombocytopenia is greater than  $30 \text{ G/L}$ , as a significant response (doubling of the platelet count) is a strong argument in favour of the immunological mechanism of thrombocytopenia [18].

##### 7.2. First-line treatment

The aim is to raise the platelet count in cases of thrombocytopenia  $< 30 \text{ G/L}$ . There are three treatment options [7,18]:

- prednisone at a dose of  $1 \text{ mg/kg}$  per day for three weeks to a maximum of two months ;
- bolus methylprednisolone  $15 \text{ mg/kg}$  per day (d1  $\pm$  d2 and d3) followed by prednisone  $1 \text{ mg/kg}$  per day for three weeks when bleeding is more severe;
- venous polyvalent immunoglobulin (IVIG) at a dose of  $1 \text{ g/kg}$  per day (d1  $\pm$  d3) (based on haemorrhagic symptoms), followed by prednisone  $1 \text{ mg/kg}$  per day for three weeks.

##### 7.3. Second-line treatments

These treatments correspond to the background treatments for ITP. They are indicated when the patient's platelets are regularly below  $30 \text{ G/L}$  or below  $50 \text{ G/L}$  in the case of additional bleeding risk factors [18].

- During the acute ITP phase, in the event of early relapse after administration of first-line treatments, treatment is poorly codified.

Withholding treatment may be considered if thrombocytopenia is isolated, without haemorrhagic manifestations and in the absence of comorbidity[18].

- During the persistent ITP phase, if previous treatments have failed, rituximab is widely used before splenectomy.

Little is known about the long-term efficacy and safety of this treatment.

- During the chronic ITP phase (ITP > 12 months), since the probability of spontaneous cure is less than 5%, splenectomy should be discussed if previous lines of treatment have failed.
- If splenectomy fails, certain treatments that were ineffective prior to splenectomy should be tried here.

At this stage, the most effective treatments are thrombopoietin TPO receptor agonists. These treatments have reduced the need for the immunosuppressive drugs that patients with severe refractory ITP were receiving until a few years ago[18].

---

## 8. Conclusion

ITP is a hematological emergency. No test can by itself confirm the diagnosis of ITP. It is a diagnosis of elimination. First-line treatment is based on polyvalent immunoglobulins or corticosteroids. Severe hemorrhagic forms are rare, but require emergency treatment. Treatment depends on the severity of the hemorrhagic syndrome and the impact on quality of life. The development of new biotechnological therapeutic approaches such as anti-CD20 and TPO antagonists has revolutionized the therapeutic management of chronic ITP.

---

## Compliance with ethical standards

### *Disclosure of conflict of interest*

The authors declare no conflicts of interest

---

## References

- [1] Sandal R, Mishra K, Jandial A, Sahu KK, Siddiqui AD. Update on diagnosis and treatment of immune thrombocytopenia. *Expert Rev Clin Pharmacol*. 4 mai 2021;14(5):553-68.
- [2] Yuan YP, Yang X, Chen YJ. Research Advances on the Pathogenesis of Primary Immune Thrombocytopenia—Review. *Zhongguo Shi Yan Xue Ye Xue Za Zhi*. 2019;27(5):1706–1710.
- [3] Cooper N, Ghanima W. Immune Thrombocytopenia. Solomon CG, éditeur. *N Engl J Med*. 5 sept 2019;381(10):945-55.
- [4] Boutroux H., Leblanc T., Courcoux M.-F. et al. Mise au point : le purpura thrombopénique immunologique de l'enfant. *Journal de pédiatrie et de puériculture*. 2018;31:79–85
- [5] Moulis G, Palmaro A, Montastruc JL et al. Epidemiology of incident immune thrombocytopenia: a nationwide population-based study in France. *Blood* 2014; 124(22):3308–3315.
- [6] Kühne T., et al. Diagnosis and management of immune thrombo-cytopenia in childhood. *Hamostaseologie*. 2017.
- [7] Singh A, Uzun G, Bakchoul T, et al. Thrombocytopenie immunitaire primaire : nouvelles perspectives sur la physiopathologie et la prise en charge de la maladie. *J Clin Med*. 2021;10(4):789.
- [8] Kohli R., Chaturvedi S. Epidemiology and Clinical Manifestations of Immune Thrombocytopenia. *Hamostaseologie*. 2019;39(3):238-249.
- [9] Audia S, Saas P, Bonnotte B. Mécanismes immunologiques impliqués dans la thrombopénie immunologique résistante au rituximab. *médecine/sciences*. 2014 Mars;30(3):239-42.
- [10] Audia S, Lorcerie B, Godeau B, Bonnotte B. Physiopathologie du purpura thrombopénique immunologique. *Rev Médecine Interne*. juin 2011;32(6):350-7.
- [11] Lambert MP, Gernsheimer TB. Clinical updates in adult immune thrombocytopenia. *Blood*. 25 mai 2017;129(21):2829-35.

- [12] Moulis G, Guénin S, Limal N, et al. Seasonal variations of incident primary immune thrombocytopenia in adults: An ecological study. *Eur J Intern Med.* 2017 Jan 1;37:e26–8.
- [13] Alam MM. Idiopathic thrombocytopenic purpura in children: a 10 years' experience at tertiary care hospital. *J Pak Med Assoc.* 2014 Dec;64(12):1358-1362
- [14] Harroche A., Rothschild C. Diagnostic d'un syndrome hémorra-gique de l'enfant. *Journal de Pédiatrie et de Puériculture.* 2019
- [15] Onisâi M, Vlădăreanu AM, Spînu A, Găman M, Bumbea H. Idiopathic thrombocytopenic purpura (ITP) – new era for an old disease. *Rom J Intern Med.* 1 déc 2019;57(4):273-83.
- [16] Song F, Al-Samkari H. Management of Adult Patients with Immune Thrombocytopenia (ITP): A Review on Current Guidance and Experience from Clinical Practice. *J Blood Med.* juill 2021;Volume 12:653-64.
- [17] Provan D, Arnold DM, Bussel JB. Updated international consensus report on the investigation and management of primary immune thrombocytopenia. *Blood Adv.* 2019;3(22):3780–3817.
- [18] Godeau B and Aladjidi N. Purpura thrombopénique immunologique de l'enfant et de l'adulte. Protocole national de diagnostic et de soins - HAS, 2017.