

Management and outcome of spontaneous cervical epidural hematoma: Case report and review of the literature

Yao Christian Hugues DOKPONOU *, Adil BELHACHMI, Fernand Nathan IMOUMBY, Alngar DJIMRABEYE, Brahim El MOSTARCHID and GAZZAZ Miloud

Department of Neurosurgery, Mohammed V Military Teaching Hospital of Rabat Morocco.

World Journal of Advanced Research and Reviews, 2021, 12(03), 094–097

Publication history: Received on 17 October 2021; revised on 03 December 2021; accepted on 05 December 2021

Article DOI: <https://doi.org/10.30574/wjarr.2021.12.3.0629>

Abstract

Spontaneous spinal epidural hematomas are rare and potentially disabling neurological emergencies. Its lead to devastating neurologic outcomes and most patient does not recover completely. The clinical presentation is diverse and includes a severe acute attack, radiating pain at the back, interscapular, or neurological deficits. We report a case of a young woman, 24-year-old, that was admitted to our department for sudden non-traumatic cervical spinal cord compression syndrome (Type A of the American Spinal Cord Injury Association “ASIA A”) including intense cervical back pain, sensory loss, and tetraplegia. Her past medical history was unremarkable. The MRI confirmed a cervical mass responsible for the spinal cord compression and the emergent surgical intervention allow us to evacuate acute C3–C7 hematoma. The patient never recovers from the neurologic deficit despite the emergent management of her case followed by functional musculoskeletal rehabilitation for two years.

Keywords: Spinal Cord Compression; Hematoma; Epidural; Spinal; Cervical Vertebrae; Case report

1. Introduction

Spontaneous spinal epidural hematomas are known as the idiopathic accumulation of blood within the spinal canal’s epidural space, causing symptoms varying from general back pain to complete paraplegia [1]. It is a very rare cause of acute spinal cord compression and is estimated to occur on yearly basis in approximately 0.1% of 100,000 individuals [2]. MRI is the radiological investigation of choice. Fifty percent of spontaneous spinal epidural hematoma patients do not fully recover and 30% of patients who presented with ASIA A classification did not improve with surgery [3]. We present a case of a 24-year-old woman who never recovers from her ASIA A spontaneous cervical epidural hematoma in spite of rapid surgical evacuation in an emergency setting, 48 hours of the tetraplegia onset.

2. Clinical case

A 24-year-old woman was admitted to our department for sudden intense cervical back pain and tetraplegia within 48 hours. The patient denies neck trauma and her past medical history was unremarkable. The physical examination revealed superficial and deep sensory palsy with the sensibility level at C4. The osteotendinous reflexes were abolished in all 4 limbs and there was acute urinary retention. There was no fever and the patient was in general good health status. This cervical spinal cord compression is classified as ASIA A (Table 1).

The cervical MRI performed in emergency showed a posterolateral right epidural masse that is heterogeneous in T1-weighted, hypointense in T2-weighted, and compressing the dural sheath from the 3rd to the 7th cervical vertebrae

* Corresponding author: Yao Christian Hugues DOKPONOU
Department of Neurosurgery, Mohammed V Military Teaching Hospital of Rabat Morocco.

(Fig. 1). These findings were suggestive of an epidural tumor lesion. The patient underwent surgical decompression the same day. Patient under general anesthesia and in a supine position, we did laminectomy at C4-C5-C6 and got directly on a bunch of clotted blood in direct contact with dura sheath. This large extradural hematoma was completely evacuated. A subsequent search for a hemorrhagic defect proved was unsuccessful.

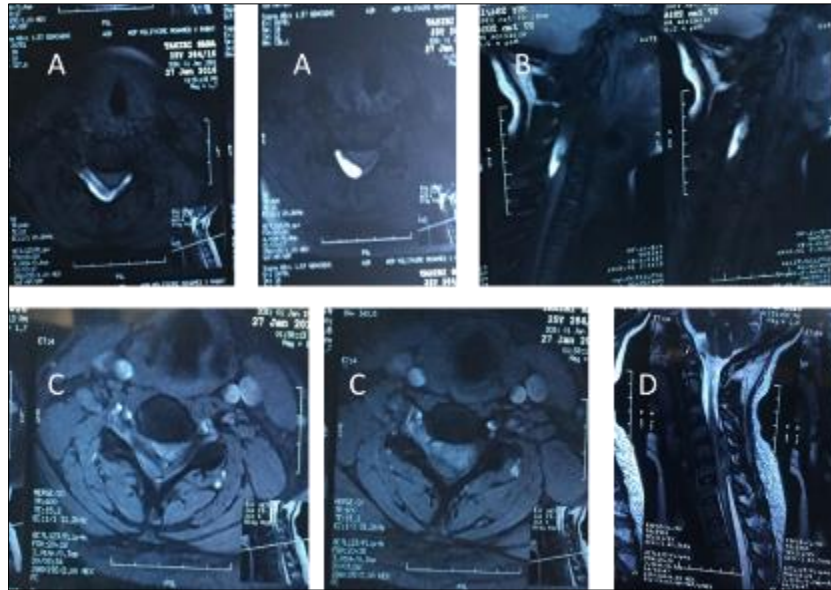


Figure 1 T1-weighted MRI of the cervical spine showing hyperintense epidural fluid collection; identified posterior to the cord and eccentric toward the right on A/axial view and B/sagittal view, at the C4-C7 levels measuring up to 2 cm thick. The cord appears compressed most pronounced at the C5 and C6 levels.

T2-weighted MRI of the cervical spine showing hypointense lesion on C/axial and D/sagittal view of same characteristics as previous

A detailed rehabilitation schedule was established for the early rehabilitation program, which included a passive joint range of motion training of lower limbs, active joint range of motion training of upper limbs, muscle strength enhances training, pulmonary function training, and position change training. In spite of intense postoperative rehabilitation, the patient remained at grade ASIA A classification with severe sequelae after 2 years.

3. Discussion

Taking the patient directly from ICU to the OR for emergency cervical decompression by laminectomy of C4-C5-C6 for spontaneous cervical hematoma revealed by sudden tetraplegia is the best medical decision to manage this kind of patient with the hope that the patient will definitely recover from the nervous assault after surgery. But that was just a hope that may or may not be all the patient's reality even though happen to be the same case. MRI is the gold standard radiological investigation for patients presenting with signs and symptoms of spinal cord injury. The spontaneous cervical hematoma was of high intensity or heterogeneous in T1-weighted and low intensity in T2-weighted in most findings [4–6]. Different theories have supported that the internal epidural plexus is responsible for the bleed into the epidural space. This may explain the heterogeneity of the lesion on T1-weighted for the mixture of old blood clots and the persistent venous bleeding.

Patients who present with more severe symptoms within a shorter time frame tend to have larger hematomas; these are associated with worse outcomes, particularly when four or more spinal segments are involved [7–9]. And these were the same findings of our reported case. A literature review by Figueroa et DeVine (10) has shown that some individuals presenting with an ASIA A deficit have demonstrated recovery. So, the decision of surgery for spontaneous spinal hematoma must not depend on the heaviness of the neurological deficit neither on the time wasted by the patient before seeking medical care; for the simple reason that some of these patients do recover after surgery. Many authors reported surgical management by decompressive laminectomy and hematoma evacuation [4,5,11,12]. But the results were quite diverse and different from one patient to another even if they do have the same clinical presentation. Nevertheless, Hongo et al [13] performed hematoma removal and decompression by corpectomy from the front of C3–C5 at approximately 32 h after the onset of symptoms and the patient was able to stand and walk 3 days after the

operation without fixation. It may be possible that the extent of recovery does not depend only on the heaviness of the nervous palsy prior to surgery but also on the surgical technique used for the decompression of the dural sheath, nerves, and nerve roots.

Patients with minimal symptoms prior to therapy are more likely to acquire complete recovery than those with major deficits in sensorimotor functioning. A hallmark prognostic indicator of pretherapy neural deficits is the ASIA score. Baesa *et al* [14] reported significant recovery with conservative therapy for selected patients with a mild to moderate neurological deficit who demonstrated early neurological improvement. Kim *et al* [15] concluded that conservative therapy could be feasible for selected patients with an ASIA score of C, D, or E demonstrating spontaneous early neurological recovery. While the ASIA A or B patients should undergo emergent decompressive surgery. However, decompressive laminectomy should continue to remain readily available, given the inverse correlation between the operative interval and better recovery.

4. Conclusion

Urgent surgical decompression is the treatment of choice for spontaneous cervical epidural hematoma with a neurological deficit. Which patient not to operate in the emergency setting is still controversial?

Compliance with ethical standards

Authors' contributions

Yao Christian Hugues DOKPONOU: Conceptualization, Writing original draft, & editing. Adil BELHACHMI: Writing, review & editing. Fernand Nathan IMOUMBY: Writing, review & editing. Alngar DJIMBRABYE: Review & editing. Brahim El MOSTARCHID: Writing & editing. Miloudi GAZZAZ: Supervision, Validation, & review.

Disclosure of conflict of interest

The authors declare that they have no conflicts of interest.

Statement of informed consent

Informed consent was obtained from all individual participants included in the study.

References

- [1] Fiani B, Jarrah R, Fiani NJ, Runnels J. Spontaneous cervical epidural hematoma: Insight into this occurrence with case examples. *Surg Neurol Int.* 2 Mar 2021; 12: 79.
- [2] Taha MM, Elsharkawy AM, Al Menshawy HA, AlBakry A. Spontaneous cervical epidural hematoma: A case report and review of literature. *Surg Neurol Int.* 13 Dec 2019; 10: 247.
- [3] Raasck K, Habis AA, Aoude A, Simões L, Barros F, Reindl R, et al. Spontaneous spinal epidural hematoma management: a case series and literature review. *Spinal Cord Ser Cases.* 2 Feb 2017; 3(1): 1–6.
- [4] Morimoto D, Kim K, Kubota A, Kokubo R, Iwamoto N, Hattori Y, et al. Recurrent Cervical Spinal Epidural Hematoma: Case Report and Literature Review. *NMC Case Rep J.* 15 Sep 2020; 7(4): 157–60.
- [5] Mathais Q, Esnault P, Cruc M, Bernard C, Prunet B, Gaillard PE. Spontaneous Cervical Spinal Epidural Hematoma Associated with Dabigatran. *World Neurosurgery.* 1 Apr 2018; 112: 264–6.
- [6] Li C, He R, Li X, Zhong Y, Ling L, Li F. Spontaneous spinal epidural hematoma mimicking transient ischemic attack. *Medicine (Baltimore).* 8 Dec 2017; 96(49): e9007.
- [7] Bakker NA, Veeger NJ, Vergeer RA, Groen RJ. Prognosis after spinal cord and cauda compression in spontaneous spinal epidural hematomas. *Neurology.* 2015; 84(18): 1894–903.
- [8] Rajz et al. Spontaneous spinal epidural hematoma: The importance of preoperative neurological status and rapid intervention. *Journal of Clinical Neuroscience.* 1 Jan 2015; 22(1): 123–8.
- [9] Shah JA, Patel NN, Michael KW. Spontaneous Spinal Epidural Hematoma: An Atypical Clinical Presentation and Discussion of Management. *Int J Spine Surg.* Apr 2020; 14(2): 158–61.

- [10] Figueroa J, DeVine JG. Spontaneous spinal epidural hematoma: literature review. *J Spine Surg.* Mar 2017; 3(1): 58–63.
- [11] Naeem A, Hanson J, Freebody J, Schutz A, O'Brien B. Spontaneous cervical epidural haematoma—diagnosis as unexpected finding by CT: case series. *Quant Imaging Med Surg.* Dec 2019; 9(12): 1986–91.
- [12] Tamburrelli FC, Meluzio MC, Masci G, Perna A, Burrofato A, Proietti L. Etiopathogenesis of Traumatic Spinal Epidural Hematoma. *Neurospine.* Mar 2018; 15(1): 101–7.
- [13] Hongo T, Iseda K, Tsuchiya M, Inaba M, Nozaki S, Takahashi K, et al. Two cases of spontaneous cervical epidural hematoma without back or neck pain in elderly Japanese men. *Acute Medicine & Surgery.* 2018; 5(2): 181–4.
- [14] Baesa S, Jarzem P, Mansi M, Bokhari R, Bassi M. Spontaneous Spinal Epidural Hematoma: Correlation of Timing of Surgical Decompression and MRI Findings with Functional Neurological Outcome. *World Neurosurgery.* 1 Feb 2019; 122: e241–7.
- [15] Kim T, Lee CH, Hyun SJ, Yoon SH, Kim KJ, Kim HJ. Clinical outcomes of spontaneous spinal epidural hematoma: a comparative study between conservative and surgical treatment. *J Korean Neurosurg Soc.* 2012; 52: 523-527.