

## New strategies of meniscal tears management: A review study

Assama Riaz \*, Dinali Obeysekera and Maya Itani

*MUA Medical School, (Medical University of the Americas), C/O R3 Education Inc. 27 Jackson Road, Suite 302 Devens, Massachusetts 01434, United States.*

World Journal of Advanced Research and Reviews, 2021, 10(03), 033–041

Publication history: Received on 17 April 2021; revised on 30 May 2021; accepted on 02 June 2021

Article DOI: <https://doi.org/10.30574/wjarr.2021.10.3.0234>

### Abstract

The incidence of meniscal tear injuries is rising, predominately due to the sporting activities of young adults. There are different methods in orthopedics of meniscal tear management. An Arthroscopic Partial Meniscectomy (APM) is the most practiced orthopedic procedure globally. However, recent literature reported serious concerns about its positive outcome. Meniscal repair is another recommended technique and growing rapidly due to its less incision requirement. Partial Meniscal implant is a modern management strategy with the excellent outcomes but still required further large-scale research.

Concluding to the modern strategies of meniscus tear management “Save the meniscus!” is the emerging approach. This review critically analyzed the most adapted management strategies of meniscal tear and the emerging ones.

**Keywords:** Meniscus tear; Treatment; Management; Modern treatment; New strategies

### 1. Introduction

Meniscal tear is the most commonly reported pathology of the knee joint with a yearly incidence of 66 per 100000 [1, 2]. The affected groups are generally the young people, sports personnel, and elderly ones with an excessive annual cost burden [3]. Initially, it was assumed that a meniscus has no functional ability and mostly responded to open total meniscectomy [4]. Reportedly, there are two menisci in the literature, U-shaped (medial) and S-shaped (lateral) [2]. The associated risk factors are also summarized in two ways with firm supporting evidence; first is the male gender, older age > 60 years, activity-related kneeling, stairs climbing, and squatting. The other one is the daily sitting activity for more than 2 hours at least, minimizing the risk of Meniscal tears strongly [1, 5]. Additionally, the acute presentation of Meniscal tear is associated with playing sports like soccer and rugby, and 12 months time span between Anterior Cruciate Ligament (ACL) injury and its alignment and reconstruction [1, 5].

A comprehensive clinical examination, especially the patient’s history gives the major clue of the meniscal tear. Patient of meniscal tear usually presents with a complaint of pain, swelling, sensation or sound during injury. The usual mechanical symptoms are popping, range limitation during movement, joint lock, catching, etc. The important factor which should be considered during treatment, that severity and type of pathology are not linked with symptoms and clinical presentation of the patient [6].

The classification of meniscal tears depends upon its orientation, etiology, and MRI; and presented as vertical longitudinal, vertical radial, horizontal, oblique, or complex [3, 7]. The International Society of Arthroscopy, Knee Surgery, and Orthopedic Sports Medicine classifies the meniscal tear in a concise, and reliable manner depends upon

\* Corresponding author: Assama Riaz

MUA Medical School, (Medical University of the Americas), C/O R3 Education Inc. 27 Jackson Road, Suite 302 Devens, Massachusetts 01434, United States..

the depth of tear, its pattern, length, radial position, and tissue quality [8]. The traumatic longitudinal-vertical and degenerative tears are usually found in active young individuals and in elderly people. The most usual sites seen are the medial meniscus and the posterior horn of the menisci [3, 9].

There are many strategies reported for the management of meniscal tears, some are traditional and some modern ones. The management decision depends upon several factors; such as patient's age, level of physical activity, lifestyle, health status, associated risks, location, type of lesion, tissue quality, etc. An orthopedic surgeon should gather all information of history, examination, radiological findings, and clinical expertise to finalize a management decision [1, 3].

The adapted management ways of Meniscal tears are;

- Non-operative management
- Operative management
- Meniscectomy (open versus arthroscopic, total versus partial)
- Meniscal repair
- Meniscal reconstruction
- Meniscal scaffolds
- Meniscal allograft transplantation (MAT) [1, 3].

### **1.1. Non-operative management**

Minor outlying tears in young individuals can be managed without surgical procedures. The trouble in these cases is to decide the stability of the tear. Studies reported that stable and firm vertical tears of the peripheral areas have potentially high healing responses [10]. Physiotherapy is another helpful approach in individuals with degenerative meniscus tears. In the former circumstances, the 'PRICE' process was followed. PRICE is the "protection, rest, ice, compression, elevation" protocol. This non-operative management protocol was advisable to follow for approximately three to six months. Anti-inflammatory and analgesic therapeutics, strengthening of quadriceps, modification of daily activities, unloader bracing and intra-articular injectable shots, etc. are helpful ways of non-operative management. In case, of unsuccessful outcome of a non-operative procedure, the surgical or operative management procedure will choose, according to the patient's condition [1, 11, 12].

### **1.2. Operative management**

Operative management includes Total meniscectomy, Open repair, Arthroscopic repair, Meniscal rasping, Meniscal suturing, Meniscal suturing techniques (Outside-in meniscal suturing techniques, and Inside-out meniscal suturing techniques) [13].

#### *1.2.1. Total meniscectomy*

Total meniscectomy is the obsolete treatment choice and rarely practiced now. The development of arthroscopic techniques better understand the biomechanics of meniscal tear and treatment option shifted towards the shielding of the meniscus tissue rather than its removal [3, 13].

#### *1.2.2. Open repair*

Open repair was one of the initial procedures of meniscus tear repairing [15].

#### *1.2.3. Arthroscopic repair*

An Arthroscopic Partial Meniscectomy (APM) is currently the most adapted technique of meniscal tear management and one of the most performed surgical procedures in orthopedics [13, 14]. Though, new scientific studies reported that APM does not have a superior outcome after a sham/placebo surgical procedure [16]. Many other scientific studies labeled it as a useless procedure, and which also endorsed by recent guidelines and recommendations in opposition of this surgical procedure [17].

#### *1.2.4. Meniscal rasping*

Meniscal rasping is followed to clean the shred outlines of the meniscus. This procedure is mostly advisable in stable and longitudinal meniscal tears, seen in the vascular regions. If a patient had an unstable knee or rupturing seen in the vascular region, this approach is not suitable [13].

### *1.2.5. Meniscal suturing*

Traditionally, meniscal suturing gives the most satisfactory results in longitudinal tears. Stable knee is the most important recovery indicator. Meniscal suturing in unstable knee leads to treatment failure. Recent studies also reported positive outcomes of meniscal repair in cases of full-thickness radial tears [18].

### *1.2.6. Meniscal suturing techniques - Outside-in meniscal suturing techniques*

This was the primary arthroscopic node methodology and now the minimum used technique. This was fit for middle and anterior tear found 1/3 section of the meniscus. The disadvantage of this technique is to trouble in reaching the extended tears [13].

### *1.2.7. Meniscal suturing techniques - Inside-out meniscal suturing techniques*

This technique has vast application and can be adapt to tears of every site, but more reliable for rear and middle 1/3 section tears. The disadvantage of this technique is the requirement of second incision and this technique is also dangerous in the posterior insertion of the meniscus [13].

This systemic review was designed to see the evolution in management strategies of meniscal tear from past to the new decade.

## **1.3. Meniscal Allograft Transplantation [MAT]**

MAT is also emerging these days but it's actually not a new idea. It was initially reported in the beginning of 1990s [3]. International Meniscus Reconstruction Experts Forum developed recommendations of MAT indications in 2015 [3]

---

## **2. Methods**

### **2.1. Study Selection Criteria**

Two authors were designated to perform an extensive data search in electronic databases including Cochrane, Pubmed, and Google scholar up to December 2020. No restrictions of age, gender, and language were imposed. Diverse keywords were used to avoid any data loss (Meniscal tears and Management OR Meniscal tears and treatment OR Meniscal tear OR Meniscal tear and management techniques OR Meniscal tear and techniques).

### **2.2. Inclusion and Exclusion Criteria**

The defined inclusion criteria was (1) Published studies on the management of meniscal tears and evaluating any specific techniques (2) No age and gender restriction, People of all age groups and both genders were included (3) All management strategies either surgical or non-surgical were used. (4) All studies must be published as full-text studies (5) all included studies were published in the English language.

The exclusion criteria was: (1) Incomplete Studies (2) Any poster, oral or Scientific Conference Presentations (3) Opinion articles, and Case reports (4) Reviews and Meta-analysis.

### **2.3. Study selection**

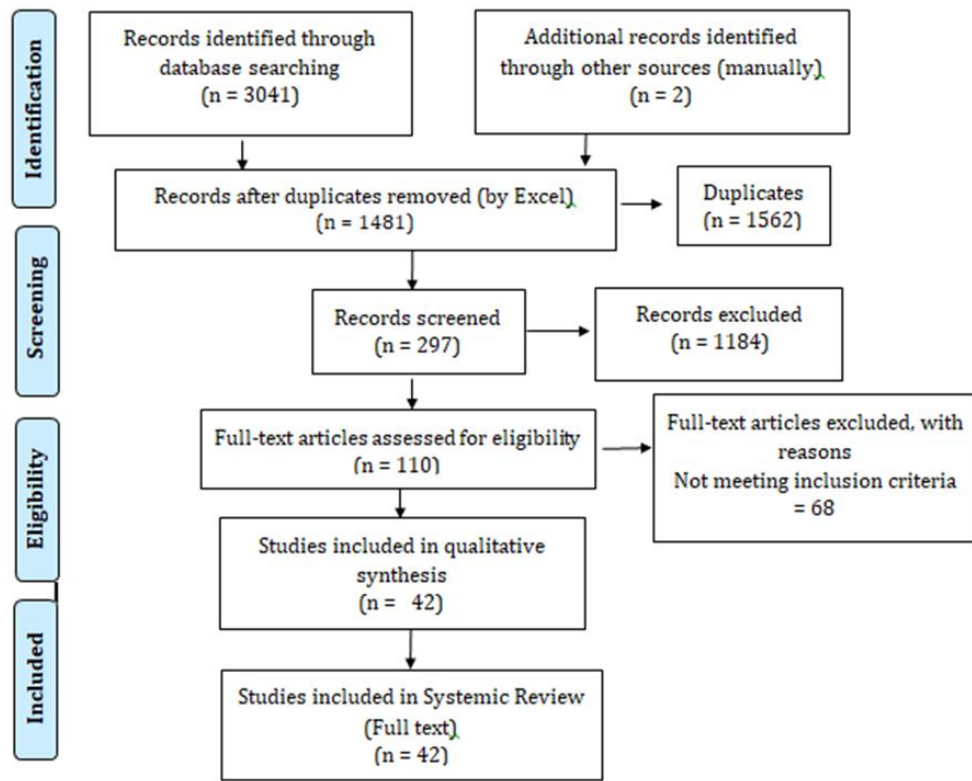
Two authors independently screen the extracted data and compile the study selection. Disagreements were identified and resolved by mutual discussion of all authors and agreement done for final selection of studies. The full version of selected articles was retrieved for further evaluation and selection confirmation.

### **2.4. Data extraction**

Data was extracted twice by two different authors as per defined criteria and keywords, to avoid any risk of bias [19].

### **2.5. Methodology Statement**

This review has following the Preferred Reporting Items for Systematic Reviews and Metanalysis (PRISMA) statement for selection process of studies [15]. There were no restrictions imposed on different population group, race, origin, ethnicity, and language. PRISMA flow diagram preferred Reporting Items for Systematic Review and Meta-Analysis



**Figure 1** Summary of Study Selection Process

**Table 1** Characteristic of selected studies

S. No	Author's Name, year, and Reference	Intervention
1	Rubman et al., 1998 [21]	Inside-out
2	Albrecht-Olsen and Bak 1999 [22]	Suture technique: Arrow: & IO: 34
3	Noyes et al., 2000 [23]	Inside-out suture repair
4	Gill et al., 2002[24]	Meniscus Arrow
5	Jones et al., 2002 [25]	Meniscus Arrow
6	Spindler et al., 2003 [26]	Suture technique: Arrow & IO
7	Kurzweil et al., 2005 [27]	Meniscus Arrow
8	Barber et al., 2005 [28]	Suture technique: Arrow, IO, Arrow + IO
9	Lee et al., 2005 [29]	Meniscus Arrow
10	Kotsovolos et al., 2006 [30]	FasT-Fix
11	Hantes et al., 2006 [31]	Suture technique: IO, & AI
12	Siebold et al., 2007 [32]	Meniscus Arrow
13	Bryant et al., 2007 [33]	Suture technique: Arrow, & IO
14	Choi et al., 2009 [34]	Suture technique: AI & IO
15	Ahn et al., 2010 [35]	Repair, all inside
16	Tachibana et al., 2010 [36]	Fast-Fix

17	Gallacher et al., 2010 [37]	All-inside Clear fix, FasT-fix sutures & Both
18	Han et al., 2010 [38]	Partial meniscectomy
19	Konan et al., 2010 [39]	Meniscus Arrow, FasT-Fix
20	Kim et al., 2011 [40]	Partial meniscectomy vs pull-out repair
21	Noyes et al., 2011 [41]	Inside-out vertical divergent sutures
22	Kim et al., 2011 [42]	Suture anchor repair vs pull-out suture repair
23	Osteras et al., 2012 [43]	Arthroscopic Partial Meniscectomy vs Physical Therapy
24	Herrlin et al., 2012 [44]	Arthroscopic Partial Meniscectomy vs Physical Therapy
25	Yim et al. 2013 [45]	Arthroscopic Partial Meniscectomy vs Physical Therapy
26	Katz et al. 2013 [46]	Arthroscopic Partial Meniscectomy vs Physical Therapy
27	Lee et al., 2014 [47]	Mason-Allen stitch repair vs simple stitch repair
28	Ma et al., 2015 [48]	Pull-out repair vs conservative
29	Ahn et al., 2015 [49]	Pull-out repair vs Conservative
30	Chung et al., 2015 [50]	Partial meniscectomy vs pull cut repair
31	Tjoumakaris et al., 2015 [51]	Repair, pull-out
32	Van de graaf et al. 2016 [52]	Arthroscopic Partial Meniscectomy vs Physical Therapy
33	Kise et al. 2016 [53]	Arthroscopic Partial Meniscectomy vs Physical Therapy
34	LaPrade et al., 2017 [54]	Pull-out repair of lateral vs medial
35	Chung et al., 2017 [55]	Meniscus repair- increased extrusion vs decreased extraction
36	Krych et al., 2017 [56]	Meniscectomy vs conservative
37	Alaia et al., 2017 [57]	Repair, transtibial
38	Keyhani et al., 2018 [58]	Suture anchor repair vs conservative
39	Lee et al., 2018 [59]	Repair, pull-out
40	Chung et al., 2018 [60]	Repair, pull-out
41	Lee, 2019 [61]	Progression to total knee arthroplasty [TKA] post meniscectomy vs no progression to TKA post meniscectomy
42	Furumatsu et al., 2019 [62]	Repair, FasT-Fix vs FasT-Fix Modified Mason Allen (F-MMA)

IO: inside-out, OI: outside-in, AI: all-inside, total knee arthroplasty (TKA), modified Mason-Allen suture (MMA) technique, FasT-Fix combined with the Ultrabraid (F-MMA).

### 3. Results and discussion

The data from selected studies suggested that from 1998 till now; after evaluating 2 decades of meniscal tear management, suturing technique and the Arthroscopic Meniscectomy was the most adapted ones, see Table 1. Arthroscopic Meniscectomy and Meniscal repair specifically seen mostly in the last decade. However, different studies adapted other comparative methods also such as Physical therapy and conservative methods. The recent studies also reported the evaluation of TKA, F-MMA.

There are different modern approaches published which reportedly have a better outcome and designed due to related disadvantages of conventional treatment options. Meniscus fixators are one of the methods which evolve due to the related concerns of incisions and vascular complications of the sewing method. This method is technically more superior with no complexities of incision and vascular problems. There are some serious concerns also associated with Meniscus fixators such as reduced mechanical force, and destruction of articular cartilage [13].

There are some healing methods which also described in the literature to provide relief in meniscal tear. These methods are Fibrin clot technique, Trephination technique, Synovial abrasion, Synovial flap transfer, Texture adhesives, Growth factors in the meniscus repair, Rehabilitation in patients with meniscus repair, Scaffolds, Meniscus transplantation, and Allograft transplantation.

### 3.1. Modern Management Approach

The current scientific literature emphasizing the shifting of meniscus management from resection to preservation, repair, rectify, and reconstruction. However, several factors influence this approach such as patient's age, associated comorbidities, presenting symptoms, meniscus type, and location [63]. Meniscal repair is one of the recommended techniques from the listed ones, having advantages of its effectiveness, and viability, and short-term outcomes with a minimum failure rate of <10%. Other techniques like suturing and meniscal fixators have failure rates of 23 to 30% [13].

Other healing reducing methods are also emerging and meniscal allografting is the most reported one. It's a complicated procedure with 89.2% follow-up survival [64]. FDA also recently approved a meniscal scaffold which is less complicated and less invasive. Partial meniscal substitute is another emerging option, which restores load balance across the knee and creates a chondroprotective effect [13].

---

## 4. Conclusion

Meniscal tears, although a most frequent orthopedic concern, still a challenge to manage. The management of meniscal tears is evolving from the 1800s which leads to total resection in the 1970s. Presently, the modern approach of meniscal management is "Save the meniscus" rather take it out. This "Save the meniscus" approach leads to new and better alternatives in the coming future.

---

## Compliance with ethical standards

### *Acknowledgments*

All authors equally contributed and acknowledge to read and approved the study.

### *Disclosure of conflict of interest*

No conflict of interest is reported.

---

## References

- [1] Mordecai SC, Al-Hadithy N, Ware HE, Gupte CM. Treatment of meniscal tears: An evidence based approach. *World J Orthop.* 2014; 5(3): 233-241.
- [2] Hede A, Jensen DB, Blyme P, Sonne-Holm S. Epidemiology of meniscal lesions in the knee. 1,215 open operations in Copenhagen 1982-84. *Acta Orthop Scand.* 1990; 61: 435-437.
- [3] Doral MN, Bilge O, Huri G, Turhan E, Verdonk R. Modern treatment of meniscal tears. *EFORT Open Rev.* 2018; 3(5): 260-268.
- [4] Mc Dermott ID, Amis AA. The consequences of meniscectomy. *J Bone Joint Surg Br.* 2006; 88: 1549-1556.
- [5] Snoeker BAM, Bakker EWP, Kegel CAT, Lucas C. Risk factors for meniscal tears: a systematic review including meta-analysis. *J Orthop Sports Phys Ther.* 2013; 43: 352-367.
- [6] Englund M, Guermazi A, Gale D, et al. Incidental meniscal findings on knee MRI in middle-aged and elderly persons. *N Engl J Med.* 2008; 359: 1108-1115.
- [7] Binfield PM, Maffulli N, King JB. Patterns of meniscal tears associated with anterior cruciate ligament lesions in athletes. *Injury.* 1993; 24: 557-561.
- [8] Anderson AF, Irrgang JJ, Dunn W, et al. Interobserver reliability of the International Society of Arthroscopy, Knee Surgery and Orthopaedic Sports Medicine (ISAKOS) classification of meniscal tears. *Am J Sports Med.* 2011; 39: 926-932.
- [9] Metcalf MH, Barrett GR. Prospective evaluation of 1485 meniscal tear patterns in patients with stable knees. *Am J Sports Med.* 2004; 32: 675-680.

- [10] Weiss CB, Lundberg M, Hamberg P, DeHaven KE, Gillquist J. Non-operative treatment of meniscal tears. *The Journal of Bone and Joint Surgery. American Volume*. 1989; 71(6): 811-822.
- [11] Beaufils P, Becker R, Kopf S, Matthieu O, Pujol N. The knee meniscus: management of traumatic tears and degenerative lesions. *EFORT Open Rev*. 2017; 2: 195-203.
- [12] Yim JH, Seon JK, Song EK, et al. A comparative study of meniscectomy and nonoperative treatment for degenerative horizontal tears of the medial meniscus. *Am J Sports Med*. 2013; 41: 1565-1570.
- [13] Sari A, Günaydin B, Mahsut DY. *Meniscus Tears and Review of the Literature, Meniscus of the Knee - Function, Pathology and Management*, Taiceer Abdulwahab and Karl Almqvist, IntechOpen. 2018.
- [14] Bhan K. Meniscal Tears: Current Understanding, Diagnosis, and Management. *Cureus*. 2020; 12(6): e8590.
- [15] De Haven KE, Sebastianelli WJ. Open meniscus repair. Indications, technique, and results. *Clinics in Sports Medicine*. 1990; 9(3): 577-587.
- [16] Sihvonen R, Paavola M, Malmivaara A, et al. Arthroscopic partial meniscectomy versus placebo surgery for a degenerative meniscus tear: a 2-year follow-up of the randomised controlled trial. *Ann Rheum Dis*. 2018; 77: 188-95.
- [17] Roos EM, Thorlund JB. It is time to stop meniscectomy. *Br J Sports Med*. 2017; 51: 490-1.
- [18] Bray RC, Smith JA, Eng MK, Leonard CA, Sutherland CA, Salo PT. Vascular response of the meniscus to injury: Effects of immobilization. *Journal of Orthopaedic Research*. 2001; 19: 384-390.
- [19] Higgins JP, Altman DG, Gøtzsche PC, et al. The Cochrane Collaboration's tool for assessing risk of bias in randomised trials. *BMJ*. 2011; 343: d5928.
- [20] Swartz MK. The PRISMA statement: a guideline for systematic reviews and meta-analyses. *J Pediatr Health Care*. 2011; 25: 1-2.
- [21] Rubman MH, Noyes FR, Barber-Westin SD. Arthroscopic repair of meniscal tears that extend into the avascular zone. A review of 198 single and complex tears. *Am J Sports Med*. 1998 Jan-Feb; 26(1): 87-95.
- [22] Albrecht-Olsen PM, Bak K. Arthroscopic repair of the bucket-handle meniscus: 10 failures in 27 stable knees followed for 3 years. *Acta Orthop Scand*. 1993; 64: 446-8.
- [23] Noyes FR, Barber-Westin SD. Arthroscopic repair of meniscus tears extending into the avascular zone with or without anterior cruciate ligament reconstruction in patients 40 years of age and older. *Arthroscopy*. 2000 Nov; 16(8): 822-9.
- [24] Gill SS, Diduch DR. Outcomes after meniscal repair using the meniscus arrow in knees undergoing concurrent anterior cruciate ligament reconstruction. *Arthroscopy*. 2002 Jul-Aug; 18(6): 569-77.
- [25] Jones HP, Lemos MJ, Wilk RM, Smiley PM, Gutierrez R, Schepsis AA. Two-year follow-up of meniscal repair using a bioabsorbable arrow. *Arthroscopy*. 2002 Jan; 18(1): 64-9.
- [26] Spindler KP, McCarty EC, Warren TA, Devin C, Connor JT. Prospective comparison of arthroscopic medial meniscal repair technique: inside-out suture versus entirely arthroscopic arrows. *Am J Sports Med*. 2003; 31: 929-34.
- [27] Kurzweil PR, Tifford CD, Ignacio EM. Unsatisfactory clinical results of meniscal repair using the meniscus arrow. *Arthroscopy*. 2005 Aug; 21(8): 905.
- [28] Barber FA, Johnson DH, Halbrecht JL. Arthroscopic meniscal repair using the BioStinger. *Arthroscopy*. 2005; 21: 744-50.
- [29] Lee GP, Diduch DR. Deteriorating outcomes after meniscal repair using the Meniscus Arrow in knees undergoing concurrent anterior cruciate ligament reconstruction: increased failure rate with long-term follow-up. *Am J Sports Med*. 2005 Aug; 33(8): 1138-41.
- [30] Kotsovolos ES, Hantes ME, Mastrokalos DS, Lorbach O, Paessler HH. Results of all-inside meniscal repair with the Fast-Fix meniscal repair system. *Arthroscopy*. 2006 Jan; 22(1): 3-9.
- [31] Hantes ME, Zachos VC, Varitimidis SE, Dailiana ZH, Karachalios T, Malizos KN. Arthroscopic meniscal repair: a comparative study between three different surgical techniques. *Knee Surg Sports Traumatol Arthrosc*. 2006; 14: 1232-7.

- [32] Siebold R, Dehler C, Boes L, Ellermann A. Arthroscopic all-inside repair using the Meniscus Arrow: long-term clinical follow-up of 113 patients. *Arthroscopy*. 2007 Apr; 23(4): 394-9.
- [33] Bryant D, Dill J, Litchfield R, Amendola A, Giffin R, Fowler P, Kirkley A. Effectiveness of bioabsorbable arrows compared with inside-out suturing for vertical, reparable meniscal lesions: a randomized clinical trial. *Am J Sports Med*. 2007; 35: 889-96.
- [34] Choi NH, Kim TH, Victoroff BN. Comparison of arthroscopic medial meniscal suture repair techniques: insideout versus all-inside repair. *Am J Sports Med*. 2009; 37: 2144-50.
- [35] Ahn JH, Jeong HJ, Lee YS, et al. Comparison between conservative treatment and arthroscopic pull-out repair of the medial meniscus root tear and analysis of prognostic factors for the determination of repair indication. *Arch Orthop Trauma Surg*. 2015; 135: 1265-1276.
- [36] Tachibana Y, Sakaguchi K, Goto T, Oda H, Yamazaki K, Iida S. Repair integrity evaluated by second-look arthroscopy after arthroscopic meniscal repair with the FasT-Fix during anterior cruciate ligament reconstruction. *Am J Sports Med*. 2010 May; 38(5): 965-71.
- [37] Gallacher PD, Gilbert RE, Kanis G, Roberts SN, Rees D. White on white meniscal tears to fix or not to fix? *Knee*. 2010 Aug; 17(4): 270-3.
- [38] Han SB, Shetty GM, Lee DH, et al. Unfavorable results of partial meniscectomy for complete posterior medial meniscus root tear with early osteoarthritis: A 5- to 8-year follow-up study. *Arthroscopy*. 2010; 26: 1326-1332.
- [39] Konan S, Haddad FS. Outcomes of meniscal preservation using all-inside meniscus repair devices. *Clin Orthop Relat Res*. 2010 May; 468(5): 1209-13.
- [40] Kim SB, Ha JK, Lee SW, et al. Medial meniscus root tear refixation: Comparison of clinical, radiologic, and arthroscopic findings with medial meniscectomy. *Arthroscopy*. 2011; 27: 346-354.
- [41] Noyes FR, Chen RC, Barber-Westin SD, Potter HG. Greater than 10-year results of red-white longitudinal meniscal repairs in patients 20 years of age or younger. *Am J Sports Med*. 2011 May; 39(5): 1008-17.
- [42] Kim J-H, Chung J-H, Lee D-H, Lee Y-S, Kim J-R, Ryu K-J. Arthroscopic suture anchor repair versus pullout suture repair in posterior root tear of the medial meniscus: A prospective comparison study. *Arthroscopy*. 2011; 27: 1644-1653.
- [43] Østerås H, Østerås B, Torstensen TA. Medical exercise therapy, and not arthroscopic surgery, resulted in decreased depression and anxiety in patients with degenerative meniscus injury. *J Bodyw Mov Ther*. 2012 Oct; 16(4): 456-63.
- [44] Herrlin SV, Wange PO, Lapidus G, Hållander M, Werner S, Weidenhielm L. Is arthroscopic surgery beneficial in treating non-traumatic, degenerative medial meniscal tears? A five year follow-up. *Knee Surg Sports Traumatol Arthrosc*. 2013 Feb; 21(2): 358-64.
- [45] Yim JH, Seon JK, Song EK, Choi JI, Kim MC, Lee KB, Seo HY. A comparative study of meniscectomy and nonoperative treatment for degenerative horizontal tears of the medial meniscus. *Am J Sports Med*. 2013 Jul; 41(7): 1565-70.
- [46] Katz JN, Losina E. Surgery versus physical therapy for meniscal tear and osteoarthritis. *N Engl J Med*. 2013 Aug 15; 369(7): 677-8.
- [47] Lee DW, Kim MK, Jang HS, Ha JK, Kim JG. Clinical and radiologic evaluation of arthroscopic medial meniscus root tear refixation: Comparison of the modified Mason-Allen stitch and simple stitches. *Arthroscopy*. 2014; 30: 1439-1446.
- [48] Ma Z. Surgical treatment of combined posterior root tears of the lateral meniscus and ACL tears. *Medical Science Monitor*. 2015; 21: 1345-1349.
- [49] Ahn JH, Jeong HJ, Lee YS, et al. Comparison between conservative treatment and arthroscopic pull-out repair of the medial meniscus root tear and analysis of prognostic factors for the determination of repair indication. *Arch Orthop Trauma Surg*. 2015; 135: 1265-1276.
- [50] Chung KS, Ha JK, Yeom CH, et al. Comparison of clinical and radiologic results between partial meniscectomy and refixation of medial meniscus posterior root tears: A minimum 5-year follow-up. *Arthroscopy*. 2015; 31: 1941-1950.
- [51] Tjoumakaris FP, Lombardi NJ, Tucker BS, Levi D, Austin A, Pepe MD. Medial meniscus root repair: Are we healing and how do we tell? *Orthop J Sports Med*. 2015; 3.



- [52] Van de Graaf VA, Noorduyn JCA, Willigenburg NW, Butter IK, de Gast A, Mol BW, Saris DBF, Twisk JWR, Poolman RW. ESCAPE Research Group. Effect of Early Surgery vs Physical Therapy on Knee Function among Patients with Nonobstructive Meniscal Tears: The ESCAPE Randomized Clinical Trial. *JAMA*. 2018 Oct 2; 320(13): 1328-1337.
- [53] Kise NJ, Risberg MA, Stensrud S, Ranstam J, Engebretsen L, Roos EM. Exercise therapy versus arthroscopic partial meniscectomy for degenerative meniscal tear in middle aged patients: randomised controlled trial with two year follow-up. *BMJ*. 2016 Jul 20; 354: i3740.
- [54] La Prade RF, Matheny LM, Moulton SG, James EW, Dean CS. Posterior meniscal root repairs: Outcomes of an anatomic transtibial pull-out technique. *Am J Sports Med*. 2017; 45: 884-891.
- [55] Chung KS, Ha JK, Ra HJ, Nam GW, Kim JG. Pullout fixation of posterior medial meniscus root tears: Correlation between meniscus extrusion and midterm clinical results. *Am J Sports Med*. 2017; 45: 42-49.
- [56] Krych AJ, Johnson NR, Mohan R, Dahm DL, Levy BA, Stuart MJ. Partial meniscectomy provides no benefit for symptomatic degenerative medial meniscus posterior root tears. *Knee Surg Sports Traumatol Arthrosc*. 2018; 26: 1117-1122.
- [57] Alaia M, Strauss E, Jazrawi L, Campbell K, Kaplan D. Discrepancy between radiographic and clinical outcomes at two year follow-up following transtibial medial meniscal root repair. *Arthroscopy*. 2017; 33: e34.
- [58] Keyhani S, Mardani-Kivi M, Sharafat Vaziri A. Root avulsion and para-root tear of the posterolateral meniscus: Repair versus untreated. *Curr Orthop Practice*. January 2018; 1.
- [59] Lee S-S, Ahn JH, Kim JH, Kyung BS, Wang JH. Evaluation of healing after medial meniscal root repair using second-look arthroscopy, clinical and radiological criteria. *Am J Sports Med*. 2018; 46: 2661-2668.
- [60] Chung KS, Noh JM, Ha JK, et al. Survivorship analysis and clinical outcomes of transtibial pullout repair for medial meniscus posterior root tears: A 5- to 10-year follow-up study. *Arthroscopy*. 2018; 34: 530-535.
- [61] Lee B-S, Bin S-I, Kim J-M, Park M-H, Lee S-M, Bae K-H. Partial meniscectomy for degenerative medial meniscal root tears shows favorable outcomes in well-aligned, nonarthritic knees. *Am J Sports Med*. 2019; 47: 606-611.
- [62] Furumatsu T, Okazaki Y, Kodama Y, et al. Pullout repair using modified Mason-Allen suture induces better meniscal healing and superior clinical outcomes: A comparison between two surgical methods. *Knee*. 2019; 26: 653-659.
- [63] Giuliani JR, Burns TC, Svoboda SJ, Cameron KL, Owens BD. Treatment of meniscal injuries in young athletes. *J Knee Surg*. 2011; 24: 93-100.
- [64] Bin SI, Nha KW, Cheong JY, Shin YS. Midterm and long-term results of medial versus lateral meniscal allograft transplantation: a meta-analysis. *Am J Sports Med*. 2018; 46: 1243-50.