



(CASE STUDY)



## The simple bone cyst

Saruhan Nesrin, Kosar Yasin Caglar and Gojayeva Gunay \*

*Department of Oral and Maxillofacial Surgery, Eskisehir Osmangazi University Faculty of Dentistry, Eskisehir, Turkey.*

Publication history: Received on 28 December 2018; revised on 19 January 2019; accepted on 26 January 2019

Article DOI: <https://doi.org/10.30574/wjarr.2019.1.1.0008>

### Abstract

The simple bone cyst (SBC) is an occasional non-epithelial covered lesion of the jaws, usually displays asymptotically. The term SBC is considered to be the wrong name because the incidence of previous traumas in patients with these legal qualifications is similar to that of the general population. The lesion may develop at any age, basically in the second decade; the most frequently area where is seen in the posterior mandible. We are going to inform about a case of SBC in the mandible of a 14-year-old female patient and its treatment with surgical exploration which was done under local anesthesia and hemorrhage provided by curettage.

**Keywords:** Simple bone cyst; Giant cell lesion; Mandible; Curettage

### 1. Introduction

In 1929, Lucas and Blum illustrated the traumatic bone cyst as a first time [1]. Etiology of these cysts trauma does not seem to play a role; the incidence in patients with a history of trauma is the same as that in the general population. In 2017 WHO classification of tumors is classified as simple bone cyst (SBC) in giant cell lesions [2]. SBC's are known by different names in the literature by time: haemorrhagic, solitary, extravasion and SBC [3]. SBC is a non-epithelial lined cavity; generally occur in young patients in the second decade of life on. No differences in terms of gender are usually observed [4]. The majority of SBC has mandibular involvement in the premolar and molar regions, the latter being the most common site mandibular symphysis. Several cases have been reported previously in the anterior part of the ramus, condyle and maxilla [5].

The cause is so far unclear and various casual aspects have been submitted: bone tumor degeneration, modified calcium metabolism, inferior infection, regional change in bone development, venous barrier, enhanced osteolysis, intramedullary bleeding, regional ischemia, or a combination of such aspects [6].

Clinically, the most of SBC is asymptomatic and often found on routine radiological examination. Pain may occur in 10%-30% of patients and rarely symptoms such as tooth sensitivity, paresthesia, fistulas, dissolution of permanent teeth, displacement of the lower dental canal, and pathological fracture in the mandible may be seen [5]. It is seen in radiographies as multilocular or unilocular radiolucent lesions. Borders of the cavity are variable from well-defined to ill-defined. The characteristic feature of the lesion is radiolucent image scallop between the roots when several teeth are included [4].

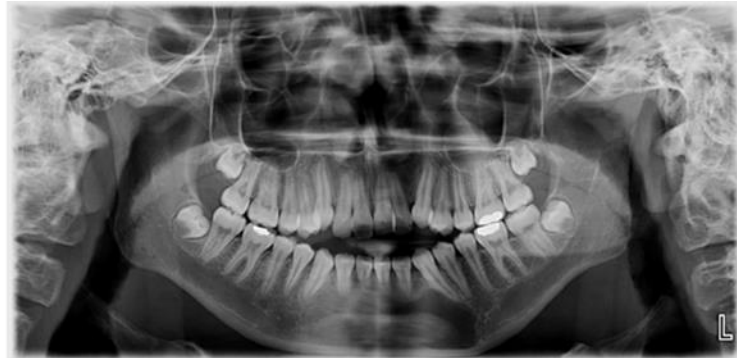Histopathological inspection revealed that the slim connective membrane with a cystic wall paternity and microscopic examination typically shows the cystic wall as a connective tissue membrane with numerous collagen fibers, with non-epithelial lining [7]. The surgical therapy consists of curettage of the bone cavity and the concomitant formation of blood coagulations [5].

\* Corresponding author

E-mail address: [gunaygojaveva@gmail.com](mailto:gunaygojaveva@gmail.com)

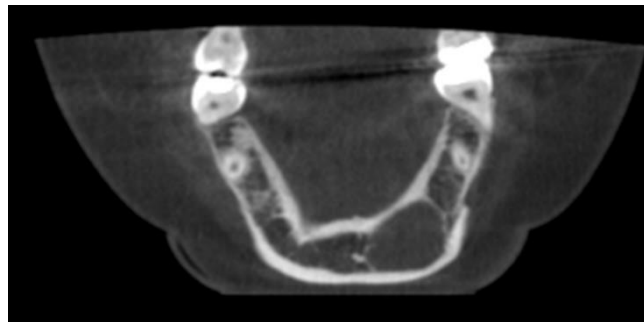
## 2. Case report

A 14-year-old female patient was referred to the Eskisehir Osmangazi University Faculty of Dentistry Department of Oral and Maxillofacial Surgery for evaluation of an unilocular radiolucency of mandibular symphysis which was discovered as part of routine radiographic examination (Figure 1).

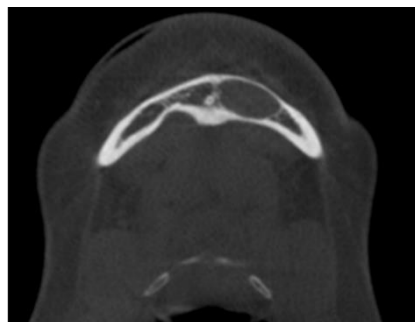


**Figure 1** Preoperative panoramic radiographic image

The lesion was asymptomatic and had no trauma history. Vitality tests showed that the associated teeth were vital. Clinical examination showed no lymphadenopathy or no swelling. Radiological examination revealed a bone cavity on the left mandible under the level of canine and canine apexes. No root resorption or displacement of the teeth was seen. On Cone-Beam Computed Tomography (CBCT) was seen 28.68 x 10.38 x 15.06 mm radiolucency lesion, no buccal or lingual expansion (Figure 2 and 3).

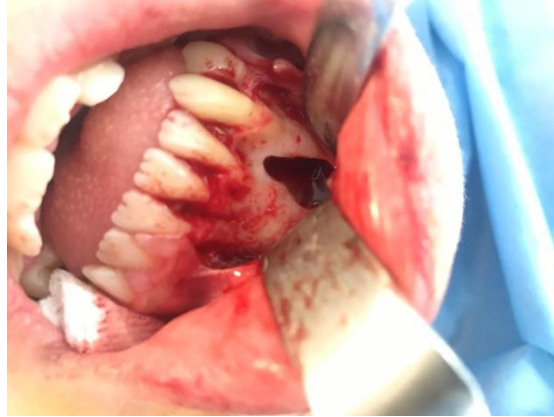

**Figure 2** Preoperative coronal CT image



**Figure 3** Preoperative axial CT image

The cavity's borders are ill-defined. Aspiration from the cystic cavity yielded no pus or serosanguineous fluid or hemorrhage. Surgical exploration was done under local anesthesia. In mandibular anterior region the mucoperiosteal flap with free gingival and vertical incisions between the canine teeth were removed and the bone surface was exposed. At the vestibule, cavity with a window shape was found to be thin and the cyst cavity was reached (Figure 4).



**Figure 4** Perioperative intraoral image

Curettage was made for haemorrhage and the flap was closed with 4–0 silk suture. The healing was uneventfully.

---

### 3. Discussion

SBC's etiopathogenesis is unclear, 3 theories is predominate: 1) an anomaly of osseous growth, 2) a degenerating tumoral process, and 3) a particular agent triggering hemorrhagic trauma [7]. Pommer propounded that intrabony hematoma formation is caused by trauma. The blood clot liquefies and enzymatic activity causes resorption to the related bone. Enzymatic activity harms adjacent bone prior to liquefaction of blood clot [8]. In our case there are no trauma history and other systemic diseases.

SBC usually predominates in the mandible posterior, extending along canine to third molar surface [5]. It is probable that most exclusive area of the mandible is correlated to its pathogenesis, according to the trauma-hemorrhage hypothesis the mandible which possesses more cortical bone, recover itself more timely in contradiction the maxilla [9]. In our case differs from the literature in that SBC was seen at mandibular anterior region.

In most cases SBC is asymptomatic and mainly discovered on routine radiographic examination. Affected teeth are often very important with no resorption or displacement. It penetrates the cortices and seldom, internal and external oral swelling can be seen [4]. On radiographic examination, SBC's are unilocular lesions with well-defined irregular borders and the classic description of "scalloping" may be seen with cystic evolvement of the dental introspace [1]. In the present case was seen no buccal or lingual expansion.

In order to distinguish aneurismal and SBC's, assurance of cavity contents such as fluid or blood [10]. In this case, there was no conformational content was found such as blood, fluid or gas.

SBC sometimes results in any complication, but the possibility of pathological fracture can't be completely excluded in larger lesions. Depending on the size of the lesion's treatment method, treatment of a smaller lesion involves surgical exploration and curettage to prove the presence of an empty space and absence of an epithelial lining [8]. For larger lesions, bone grafting or hydroxyapatite, bio-glass, etc. Other alternative ways, such as the use of synthetic materials, may achieve a congruent result [11]. Although the lesion is large, there is no cortical bone expansion so we have surgical exploration and curettage.

Histological examination is required to ensure recognition for approval. Studies conducted in a most of SBC cases have shown that 9.52% of the cases reveal the presence of a vascular occlusion and histological evaluation of the obtained material. One of the most common features of these lesions is the absence of epithelial tissue. The purpose of the histological examination is to prove the absence of epithelial tissue [12].

---

### 4. Conclusion

SBS radiologically has the same pattern and radiolucency as other destructive and invasive cysts. Therefore, it should be considered that it can be interfered with other cysts. The diagnosis and treatment plan should be determined accordingly. In this case the massive lesion is treated successfully by curettage.

## Compliance with ethical standards

### *Disclosure of conflict of interest*

All authors of the manuscript have no conflict of interests to declare.

### *Statement of informed consent*

Written and verbal confirmation was obtained from the patient.

---

## References

- [1] Ahlers E, Setabutr D, Garritano F, Adil E and McGinn J. (2013). Pathologic fracture of the mandible secondary to traumatic bone cyst. *Craniomaxillofacial trauma & reconstruction*, 6(3), 201.
  - [2] Ei-Naggar AK, Chan JK, Grandis JR, Takata T and Slootweg PJ. (2017). WHO classification of head and neck tumours. 4<sup>th</sup> Edition, International Agency for Research on Cancer, Lyon.
  - [3] Dincer O, Kose TE, Cankaya AB and Aybar B. (2012). Traumatic bone cyst mimicking radicular cyst. *BMJ case reports*, 2012, bcr2012007316.
  - [4] Nagori SA, Jose A, Agarwal B, Bhatt K, Bhutia O and Roychoudhury A. (2014). Traumatic bone cyst of the mandible in Langer-Giedion syndrome: a case report. *Journal of medical case reports*, 8(1), 387.
  - [5] Xanthinaki AA, Choupis KI, Tosios K, Pagkalos VA and Papanikolaou SI. (2006). Traumatic bone cyst of the mandible of possible iatrogenic origin: a case report and brief review of the literature. *Head & Face Medicine*, 2(1), 40.
  - [6] Satish K, Padmashree S and Rema J. (2014). Traumatic bone cyst of idiopathic origin? A report of two cases. *Ethiopian journal of health sciences*, 24(2), 183-187.
  - [7] Copete MA, Kawamata A and Langlais RP. (1998). Solitary bone cyst of the jaws: radiographic review of 44 cases. *Oral Surgery, Oral Medicine, Oral Pathology, Oral Radiology and Endodontics*, 85(2), 221-225.
  - [8] Magliocca KR, Edwards SP and Helman JI. (2007). Traumatic bone cyst of the condylar region: report of 2 cases. *Journal of oral and maxillofacial surgery*, 65(6), 1247-1250.
  - [9] Martins-Filho PR, Santos TD, Araújo VL, Santos JS, Andrade ES and Silva LC. (2012). Traumatic bone cyst of the mandible: a review of 26 cases. *Brazilian journal of otorhinolaryngology*, 78(2), 16-21.
  - [10] Kumar ND, Sherubin JE, Raman U and Shettar S. (2011). Solitary bone cyst. *Indian Journal of Dental Research*, 22(1), 172.
  - [11] Kumar LS, Kurien N and Thaha KA. (2015). Traumatic bone cyst of mandible. *Journal of maxillofacial and oral surgery*, 14(2), 466-469.
  - [12] Stimson PG and McDaniel RK. (1989). Traumatic bone cyst, aneurysmal bone cyst, and central giant cell granuloma—Pathogenetically related lesions? *Journal of endodontics*, 15(4), 164-167.
- 

## How to cite this article

Saruhan N, Kosar YC and Gojayeva G. (2019). The simple bone cyst. *World Journal of Advanced Research and Reviews*, 1(1), 23-26.

---